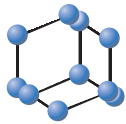
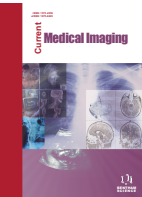

RESEARCH ARTICLE


**BENTHAM
SCIENCE**

Importance of Pre-treatment Fractional Anisotropy Value in Predicting Volumetric Response in Patients with Meningioma Treated with Gamma Knife Radiosurgery



Dilek H. Cesme^{1,*}, Alpay Alkan¹, Lutfullah Sari¹, Fatma Yabul¹, Hafize O. Temur¹, Mahmut E. Aykan¹, Mehmet H. Seyithanoglu² and Mustafa A. Hatiboglu²

¹Department of Radiology, Faculty of Medicine, Bezmialem Vakif University, Istanbul, Turkey; ²Department of Neurosurgery, Faculty of Medicine, Bezmialem Vakif University, Istanbul, Turkey

Abstract: Background: The importance of pre-treatment Diffusion Tensor Imaging (DTI) parameters in determining the response to treatment after radiosurgery in patients with meningioma has not yet been clearly revealed.

Objective: This study was conducted to determine tumor volume changes in terms of radiological response in patients with meningioma treated with Gamma Knife Radiosurgery (GKR) and to analyze the relationship between Total Tumor Volume (TTV) and Diffusion Tensor Imaging (DTI) parameters. In addition, we investigated whether the response to treatment can be predicted by pre-radiosurgery DTI findings.

Methods: Fifty-four patients were assessed using MRI and DTI before and after GKR. Mean Diffusivity (MD), Fractional Anisotropy (FA), Radial Diffusivity (RD), and TTV of tumour were determined. Patients with 10% or more decrease in TTV after GKR were classified as group 1 and those with less than 10% decrease in volume or increase in volume were considered group 2. The relationships between MD, RD, and FA values and TTV were investigated.

Results: A decrease of 46.34% in TTV was detected in group 1 after GKR, while TTV increased by 42.91% in group 2. The lowest pre-treatment FA value was detected in group 1. In addition, after GKR, FA values showed a significant increase in group 1. MD and RD values increased in both groups after radiosurgery. There was a negative correlation between pre-treatment FA, RD, and MD values after radiosurgery.

Conclusion: Detection of low FA values due to the poor fiber content in meningioma before radiosurgery may be a guide in predicting the response to treatment. Further studies are required to have a better understanding of the relationship between pre- and post-treatment follow-up FA values and tumor volume in determining the efficacy of GKR in patients with meningioma.

ARTICLE HISTORY

Received: October 07, 2020
Revised: November 26, 2020
Accepted: December 04, 2020

DOI:
10.2174/221333560899210128182047



This is an Open Access article published under CC BY 4.0
<https://creativecommons.org/licenses/by/4.0/legalcode>

Keywords: Gamma knife radiosurgery, meningioma, diffusion tensor imaging, fractional anisotropy, radiosurgery, mean diffusivity, tumor volume.

1. INTRODUCTION

Meningioma occurs in 13 to 26% of cases with primary intracranial tumors [1]. It develops from arachnoid cap cells in the dura. The most common localizations of meningiomas are convexity, parasagittal area, skull base, falx, and sphenoid bone. Treatment options include observation, surgery, conformal radiotherapy, stereotactic radiosurgery, or their combinations. Follow-up without any intervention is mostly recommended in patients who are elderly, asymptomatic, or with small size tumors [2]. Treatment is required

when it grows rapidly, invades critical structures, and becomes symptomatic.

Especially in meningiomas less than 3 cm, stereotactic radiosurgery has become an alternative safe treatment method to microsurgery due to its low risk of complications and treatment efficacy [3]. Recently, Gamma Knife Radiosurgery (GKR) has been used in even larger meningiomas (> 2.5-3 cm). It has been reported that meningioma growth is controlled between 85% and 99% in patients who have been followed up for more than 3 years after GKR [1, 4-8]. The location of the meningioma may affect the response of the tumor after radiosurgery. In parasagittal meningiomas close to critical structures that are sensitive to radiation, such as optic pathways, brainstem, and cochlea, radiosurgery should be planned more carefully. The volume

*Address correspondence to this author at the Department of Radiology, Faculty of Medicine, Bezmialem Vakif University, Istanbul, Turkey; Tel: 90 212 453 17 00; Fax: 90 212 631 85 51; E-mail: dhcesme@bezmialem.edu.tr

shrinkage in meningiomas after radiosurgery is affected by several factors such as initial tumor volume, radiation dose, patient age, and follow-up time [4, 9-11].

Diffusion Tensor Imaging (DTI) reveals important data about the diffusion direction and size of water molecules and microstructural integrity of the tissue. The most commonly used parameters are Mean Diffusivity (MD), Fractional Anisotropy (FA), and Radial Diffusivity (RD). The use of FA values in the diagnosis and during the follow-up period of patients with meningioma is controversial [1]. Various FA values have been reported in different studies depending on whether the grade on meningiomas is low or high [1, 12-14]. It has been shown that Ki-67 proliferation index and tumor cellularity are associated with MD values [1, 4]. High FA values in fibroblastic meningiomas and low FA values in endothelial meningiomas have been also reported (Table 1) [15, 16]. Response to radiation therapy has been reported to be lower in fibroblastic meningiomas with fiber-rich tissues [4].

Table 1. The correlation between the pathological findings of meningiomas and DTI parameters is summarized.

| Pathological Findings | DTI Features |
|--------------------------------|---------------------|
| High Ki-67 proliferation index | decreased MD values |
| High tumor cellularity | decreased MD values |
| Fibroblastic meningiomas | high FA values |
| Endothelial meningiomas | low FA values |

DTI; Diffusion Tensor Imaging.
MD; mean diffusivity.
FA; fractional anisotropy.

To the best of our knowledge, there are few studies in the literature evaluating the effect of radiation on meningiomas in patients treated with GKR in terms of volume changes and DTI parameters [4]. In this study, we aimed to evaluate tumor volume changes in terms of radiological response in patients with meningioma treated with GKR and analyze the relationship between TTV and DTI parameters. In addition, we investigated whether the response to treatment can be predicted by pre-radiosurgery DTI parameters.

2. MATERIALS AND METHODS

Table 2. Intracranial locations of 54 meningiomas treated with radiosurgery.

| Tumor Location | Group 1 (n:36) | Group 2 (n:18) | Total (n:54) (%) |
|---|----------------|----------------|------------------|
| Cerebello-pontine angle/ptetroclival | 8 | 2 | 10 (18.51) |
| Convexity area | 8 | 3 | 11 (20.37) |
| Tentorial cerebellar/occipital/temporal | 5 | 3 | 8 (14.81) |
| Parafalcine & parasagittal | 8 | 3 | 11 (20.37) |
| Olfactory groove meningioma | 2 | 2 | 4 (7.40) |
| Tuberculum sellae meningioma | 4 | 3 | 7 (12.96) |
| Anterior clinoidal meningioma | 1 | 2 | 3 (5.55) |

Our study was approved by the institutional ethics committee. We retrospectively gathered the data of the patients who underwent GKR treatment for meningioma between 2014 and 2020 at the Bezmialem Vakif University Hospital. Patients with meningioma who had 3D volumetric imaging before and after GKR and had follow-up MRI for 24 months or more were included in the study. Fifty-four patients (9 men, 45 women, mean age 55.14 ±10.2 years) with meningioma treated with GKR were evaluated. Patients with multiple meningiomas and a history of previous surgery were excluded from the study. Locations of the meningiomas in this patient cohort treated with GKR are presented in Table 2.

2.1. Gamma Knife Radiosurgery

All of the patients included in our study were treated in the GKR unit at Bezmialem Vakif University. The GKR procedure was performed by two experienced neurosurgeons. (MAH, MHS) using Gamma Knife 4C model (Elekta, Stockholm, Sweden). Treatment planning was carried out with GammaKnife software (Elekta, Stockholm, Sweden). Leksell stereotactic head frame was placed, and images of volumetric MRI sequences including 3D T2 and 3D T1 MPRAGE (rapid acquisition of gradient echoes prepared by magnetization; TI: 450 ms, TR: 12.5 ms, TE: 5 ms) were obtained. Images were transferred to the Gama knife planning unit, and treatment planning and dose calculations were made. All patients were treated with an average margin dose of 12.7 Gy (range: 10-14 Gy) with a 50% isodose line. The mean maximum dose was 25.78 Gy (20-36 Gy).

2.2. Magnetic Resonance Imaging

The patients with meningioma who were considered for GKR treatment were evaluated with a 1.5T MRI system (Avanto, Siemens). MRI sequences included axial and coronal FLAIR (fluid-attenuated inversion recovery) (TR [Repetition time]: 8000 ms, TE [Time Echo]: 90 ms, TI [Inversion Time]: 2500 ms), sagittal, and axial T2 TSE (TR: 4500, TE: 90 ms), axial T1 (TR: 550, TE: 14 ms) weighted images. T1 images with contrast in the axial, sagittal, and coronal plane were obtained (iv Gd-DTPA). With and without contrast, 3D T1 MPRAGE images were also used in our study.

All patients were evaluated with standard DTI parameters (single-shot SE echo-planar, TR/TE:6000/89 ms, FOV; 230 mm, matrix; 128x256 and slice thickness; 5 mm, spatial resolution; 1.54). Thirty diffusion-encoding directions were used at $b=0$ s/mm² and $b=1000$ s/mm². FA maps were created by processing DTI data on the workstation (Leonardo, Siemens). MD and RD indices were calculated from the tensor using eigenvalues: MD is $(\lambda_1+\lambda_2+\lambda_3)/3$, and RD is $(\lambda_2+\lambda_3)/2$. MD, RD, and FA values were measured by manually placing the elliptical ROIs (regions of interest) in the tumor. Volumetric contrast 3D T1 MPRAGE images were taken as a reference when placing the ROI on the tumor. The sizes of all ROIs were 27.75 ± 17.83 cm³ (median; 24 cm³). The adaptation of the size and location of all ROIs within the tumor was carried out simultaneously with two radiologists (DHC, AA) who had at least 10 years of experience. TTV was calculated by the same investigator. In our practice, the first MRI follow-up after GKR is performed after 3 months. In the following period, we monitor the patients at 12-month intervals with MRI. In our study, DTI and routine MRI were obtained 1-3 days before the GKR procedure and accepted as the baseline image. The last follow-up MRI and DTI findings obtained after GKR were compared with the baseline images in terms of MD, RD, FA, and tumor volume. The mean time between GKR and the last follow-up MRI was 35.42 ± 8.79 months (range: 24-57 months).

The TTV was analyzed by a 3D segmentation assessment in the workstation (Siemens workstation, Syngo. *via*). TTV before and after GKR was calculated from 3DT1-MPRAGE images with contrast. TTV analysis was performed in a cubic centimetre (cm³). The TTV is derived by subtracting the follow-up volume (TTV after radiosurgery; TTV_{ar}) from the initial tumor volume (TTV before radiosurgery; TTV_{br}) and dividing by the initial TTV. The change in percentage compared with baseline acquisition was calculated by change $\% = \frac{TTV_{ar} - TTV_{br}}{TTV_{br}}$.

Patients who showed 10% or more reduction (shrinkage) in tumor volume compared to the initial volume measured before radiosurgery were considered group 1 based on other published studies (Fig. 1 a-c). Cases with a decrease in volume below 10% or with a volume increase compared to pre-treatment were considered as group 2 (which did not respond adequately to treatment) (n:18) (Fig. 2 a-c). The relationships between MD, RD, and FA values and TTV were investigated.

2.3. Statistical Analysis

Statistical data were analyzed with SPSS 22.0. Kolmogorov Smirnov and Shapiro-Wilks tests were used to determine whether the data were suitable for normal distribution. The groups were compared before and after radiosurgery using the Wilcoxon test. The comparison between groups of quantitative variables was performed with Mann Whitney U test for two independent groups. The correlation of all quantitative parameters was investigated by the Spearman test. P values below 0.05 were considered statistically significant.

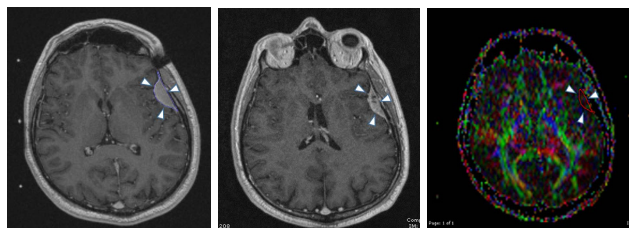


Fig. (1). Left frontal meningioma. Analysis of total tumor volume (TTV) using by the placement of a region of interest (ROI) on post-contrast 3D T1-weighted axial image (arrowheads) (a). A significant decrease in TTV is observed after 48 months follow-up after radiosurgery (arrowheads) (b). MD, RD, and FA values were calculated by placing ROI that covers the tumor completely in FA maps (arrowheads) (c). (A higher resolution / colour version of this figure is available in the electronic copy of the article).

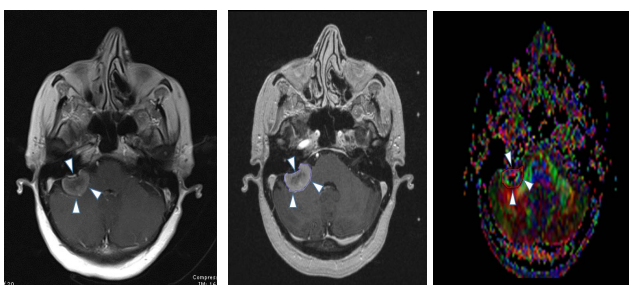


Fig. (2). Right cerebellopontine angle meningioma at pre-treatment stage on postcontrast axial T1-weighted image (arrowheads) (a). In follow-up MRI, 29 months after radiosurgery, an increase in tumor volume is observed (arrowheads) (b). ROI placement (arrowheads) is seen on the FA map to calculate DTI parameters (c). (A higher resolution / colour version of this figure is available in the electronic copy of the article).

3. RESULTS

TTV, FA, MD, and RD values were obtained from tumors in MRI before and after the treatment of patients with meningioma. Volume changes, follow-up time, marginal dose, and the maximum dose applied in those patients are presented in Table 3.

Six patients (11.1%) developed radiation-related complications. Among those patients, 5 had edema, and one had a seizure after GKR.

There was no statistically significant difference between group 1 and group 2 in terms of age and follow-up time in the patient cohort.

There was no correlation between FA and MD values before treatment ($p=0.16$). However, there was a negative correlation between FA and RD values before treatment ($p=0.002$, $r = -0.408$).

3.1. Comparison in Terms of Total Patients Before and After GKR (n:54)

In 54 patients with meningioma, TTV decreased from 5.10 ± 4.80 to 3.51 ± 2.93 after GKR treatment ($p=0.0001$) (Fig. 3). There was an average reduction of 16.59% in TTV.

There was a significant increase in MD and RD values obtained from the tumor after GKR (p=0.005 and p=0.018, respectively). There was no significant difference in FA values. There was no correlation between TTV and DTI param-

eters after radiosurgery. There was a negative correlation between FA and MD and RD values after radiosurgery (p=0.009, r= -0.353 and p=0.0001, r= -0.505, respectively) (Fig. 4 a, b).

Table 3. TTV, FA, MD, RD values obtained from the tumor before and after the treatment in patients with meningioma, follow-up time, the margin, and maximum radiation dose applied are presented.

| | | Group 1 | Group 2 |
|------------------------------|----------------|-------------|-------------|
| Mean follow-up time (month) | | 36.28±8.75 | 33.72±8.87 |
| Mean marginal radiation dose | | 12.81±0.45 | 12.50±0.79 |
| Mean maximum radiation dose | | 25.98±1.97 | 25.38±1.89 |
| TTV | Pre-treatment | 5.62±5.3 | 4.10±3.45 |
| | Post-treatment | 2.79±2.43 | 4.94±3.39 |
| FA | Pre-treatment | 0.228±0.079 | 0.271±0.035 |
| | Post-treatment | 0.289±0.143 | 0.255±0.090 |
| MD | Pre-treatment | 0.954±0.214 | 0.910±0.153 |
| | Post-treatment | 1.026±0.285 | 1.011±0.182 |
| RD | Pre-treatment | 0.840±0.220 | 0.784±0.137 |
| | Post-treatment | 0.889±0.267 | 0.883±0.178 |

TTV: Total tumor volume.
 FA: fractional anisotropy.
 MD: mean diffusivity (x 10⁻³ mm²/s).
 RD: radial diffusivity (x 10⁻³ mm²/s).
 Group 1; The group that responded to radiosurgery.
 Group 2; The group that did not respond adequately to radiosurgery.

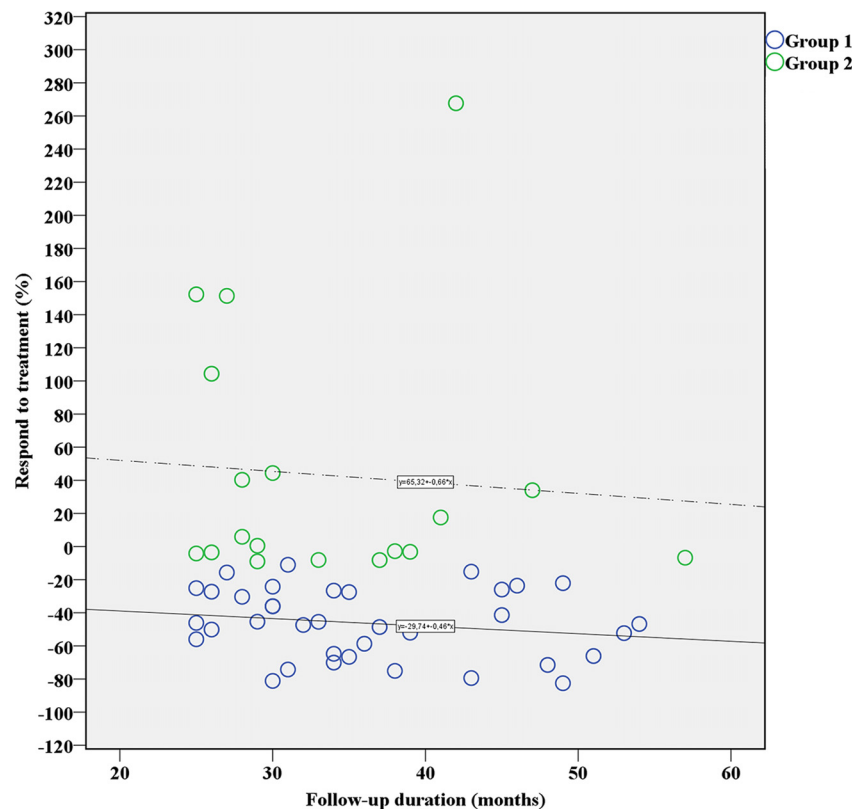


Fig. (3). The graph showing the relationship between the response to treatment of the groups and the duration of follow-up is monitored. Group 1; the group that responded to radiosurgery (blue). Group 2; The group that did not respond adequately to radiosurgery (green).

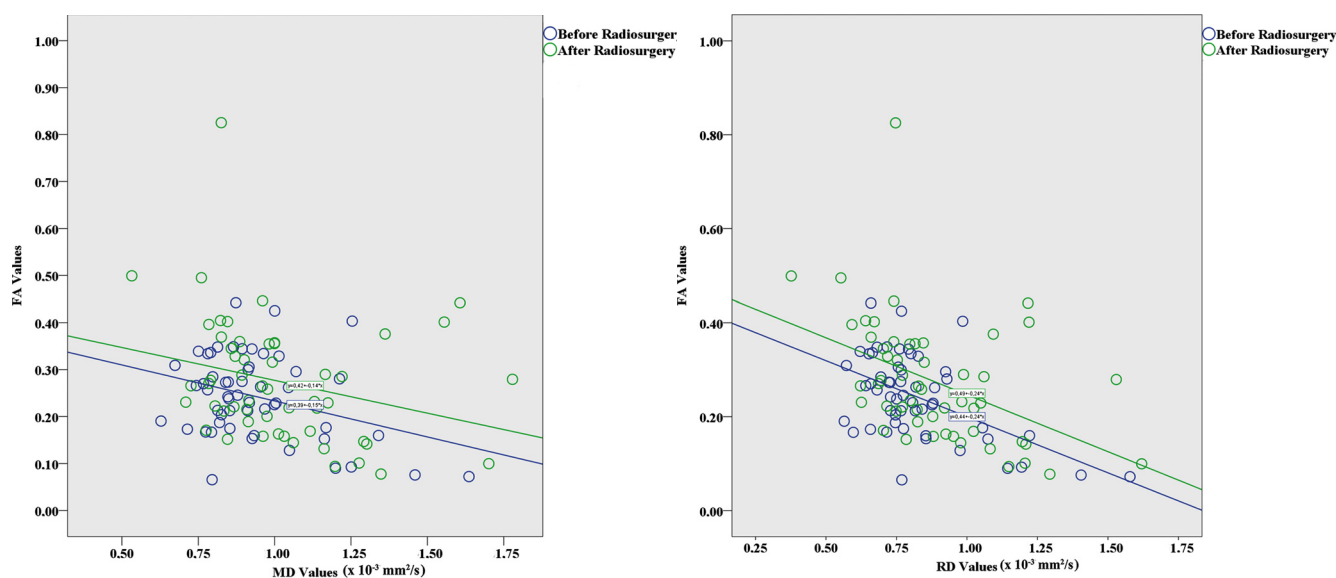


Fig. (4). The graphs showing the correlation between FA and MD (4a) and RD (4b) before and after radiosurgery are monitored.

3.2. Comparison Results Before and After GKR Treatment in Group 1 (n:36)

The average decrease in TTV was 46.34% in group 1 patients. There was a significant increase in FA values obtained from the tumor after GKR ($p=0.012$). There was a significant increase in MD and RD values obtained from the tumor after GKR ($p=0.004$ and $p=0.016$, respectively). There was a negative correlation between pre-treatment FA, and RD and MD values after radiosurgery ($p=0.005$, $r=-0.459$ and $p=0.015$, $r=-0.401$, respectively). There was a negative correlation between FA and MD and RD values after radiosurgery ($p=0.03$, $r=-0.362$ and $p=0.001$, $r=-0.512$, respectively).

3.3. Comparison Results Before and After GKR Treatment in Group 2 (n:18)

After GKR, an average of 42.91% increase was found in TTV in group 2 patients. There was a statistically increase in MD and RD values of tumor after radiosurgery in group 2 ($p=0.004$, $p=0.002$, respectively). There was no significant difference in FA values.

4. DISCUSSION

Currently, GKR has been increasingly used in the treatment of meningiomas due to the precise positioning of the lesions, good local tumor control, and preservation of neurological function [17-20]. The following criteria should be considered for eligibility of radiosurgery in patients with meningioma: lesions smaller than 3 cm or 10 cm³, presence of edema around the mass lesion (radiosurgery may increase edema), the proximity of radiation-sensitive structures such as optical pathways, brainstem, and cochlea [21].

Volumetric analysis of meningioma after radiosurgery is important for determining the treatment response [22, 23].

Radiological follow-up period intervals are controversial. It is commonly accepted that obtaining MRI every 6-12 months within 5 years from the end of the first year and an observation every 1-3 years in the following period are reasonable [22]. In our study, 36 of 54 patients with meningioma (66.6%) had a volume shrinkage above 10% after GKR. There was an average TTV reduction of 46.34% in group 1. Progression was present in 33.4% of patients with meningioma after GKR. There was an average TTV increase of 42.91% in group 2.

It is thought that radiosurgery treatment would be effective on meningiomas by reducing the replication ability of tumor cells and vascular hyalinization, resulting in fibrosis and necrosis. Inflammation and cystic changes were detected in pathological specimens obtained from meningioma after radiosurgery [21, 24]. Coagulative necrosis, edema, vasculopathy, and reactive astrocytosis have been demonstrated in biopsies performed in areas where there is no contrast enhancement after radiosurgery [21].

DTI provides important information to help us better understand the abnormalities seen in meningioma after radiosurgery [21]. DTI metrics provide important information about the degree of microstructural damage and behavioral patterns of histological tumor organization [4]. FA measures the anisotropic water diffusion. It also shows the versatility and texture integrity of water diffusion. FA provides important information about the microstructure of white matter, fiber density, axon diameter, and myelination. While MD independently measures the direction of total water diffusion in tissues, it also provides important information about tissue cellularity and nucleus-cytoplasm ratio. RD reveals the diffusivity magnitude perpendicular to the maximum diffusion direction [1]. Although FA and MD sensitivities are high in the differentiation of low and high-grade meningiomas, they do not provide very specific information in evalu-

ating microstructural tissue changes [1]. RD values reveal detailed information about diffusion changes in the microstructure of tumor tissue. High RD values were reported in low-grade meningiomas [1]. Fibroblastic meningiomas have been reported to have low MD and high FA values compared to other meningioma types [1].

FA values may guide to predict the consistency of meningioma [23, 25]. Hyperintensity in FA maps and isointense signals in MD maps are thought to be related to the firm consistency of meningioma [23]. MD values are thought to be useful in determining the grade of meningioma and progression [13, 14, 25]. It is known that increased MD values are associated with decreased tumor cellularity [4]. Decreased MD values in high-grade and atypical meningiomas may be associated with a high nucleus/cytoplasm ratio and increased cellularity [13, 14]. Meningiomas with a high proliferation index show a better response to radiosurgery compared to fiber-rich fibroblastic meningiomas [4]. Low RD, MD, and high FA values are considered to be due to the fascicular arrangement of long spindle-shaped tumor cells and high content intra-interfascicular fibers in meningiomas, which are rich in fibrous tissue [14-16]. The intracellular collagen and reticulin content are thought to be responsible for the solid consistency of fibroblastic meningiomas.

Speckter *et al.* [4] stated that the decrease in tumor volume after radiosurgery was not significant in meningiomas with high pre-treatment FA, low RD, and MD values. They emphasized that these findings may be related to decreased radiosensitivity of the tumor. It is thought that the internal structure of meningioma maybe consist of high fiber tissue content. They claimed that meningiomas with the lowest FA values before treatment had the greatest reduction in tumor volume after radiosurgery. In our study, there was a significant difference between pre-treatment FA values and post-treatment FA values in group 1. While pre-treatment FA values were 0.228 ± 0.079 , and they were 0.289 ± 0.143 after radiosurgery treatment. We think that an increase in FA together with a decrease in TTV in response to GKR treatment may be associated with radiation-induced fibrosis. Pre-treatment FA values in group 1 were lower compared to group 2. While the mean FA value before treatment was 0.228 ± 0.079 in group 1, that was 0.271 ± 0.035 in group 2. In addition, the more the pre-treatment FA values decrease in group 1, the more significant increase can occur in MD and RD values after radiosurgery. The detection of low FA values in the pre-treatment period in group 1 with the greatest decrease in TTV can be considered as an important finding, indicating that the tumor tissue may have lower fiber content. Therefore those meningiomas are more sensitive to radiation. Some researchers reported an increase in tumor volume after radiosurgery in meningiomas with high pre-treatment FA values [4]. Similarly, We found the highest FA values in group 2 before treatment. The detection of high FA values can be explained by the high content of intratumoral fibrous tissue. This finding may result in a low response to radiosurgery. Based on the findings of our study, we can speculate that there may be an increase in FA values in patients who respond to GKR and a decrease in FA values in those who do not respond well. We can conclude that TTV decrease due to radiosurgery may be less in meningiomas,

which have rich fibrous tissue and high pre-treatment FA values.

MD and RD values increased significantly after radiosurgery treatment in patients with meningioma. It is thought that high MD and RD values detected in the tumor after GKR may be associated with radiation-induced inflammation, cystic changes, and decreased tumor cellularity. The relationship between decreased TTV after radiosurgery with decreased FA and increased RD and MD values may indicate an increased sensitivity to radiation. Speckter *et al.* [4] reported that the relationship between DTI parameters and radiosensitivity in meningioma could be understood with a biopsy-based study on the underlying histology and responsible pathophysiological mechanisms.

Our study has several limitations. One of the most important limitations is that it is a retrospective study and the number of patients followed for more than three years is low. As the second limitation, since there is no histopathological diagnosis before GKR, we can only suggest that meningiomas are low or high grade, and we do not have the information about the internal structure of the tumor (especially for fibrous tissue). DTI measurements can be affected due to the heterogeneity of the tumor.

CONCLUSION

Detection of low FA values due to the poor fiber content in meningioma before radiosurgery may be a guide in predicting the response to treatment. Further studies are needed to understand better the relationship between pre- and post-treatment follow-up FA values and the tumor volume in determining the efficacy of GKR in patients with meningioma.

LIST OF ABBREVIATIONS

| | | |
|-----|---|--------------------------------|
| TTV | = | Total Tumor Volume |
| GKR | = | Gamma Knife Radiosurgery |
| DTI | = | Diffusion Tensor Imaging |
| ADC | = | Apparent Diffusion Coefficient |
| FA | = | Fractional Anisotropy |
| MD | = | Mean Diffusivity |
| RD | = | Radial Diffusivity |
| ROI | = | Region of Interest |
| MRI | = | Magnetic Resonance Imaging |

ETHICS APPROVAL AND CONSENT TO PARTICIPATE

Our study was approved by the institutional ethics committee, Bezmialem vakif university (Date; 6.17.2020 No; 10/196).

HUMAN AND ANIMAL RIGHTS

No Animals were used in this study. All the human procedures were is in accordance with the ethical standards of

the committee responsible for human experimentation (institutional and national), and with the Helsinki Declaration of 1975, as revised in 2013.

CONSENT FOR PUBLICATION

Informed consent was obtained from the patients.

AVAILABILITY OF DATA AND MATERIALS

The authors confirm that the data supporting the findings of this study are available within the article.

FUNDING

None.

CONFLICT OF INTEREST

The authors declare no conflicts of interest, financial or otherwise.

ACKNOWLEDGEMENTS

Declared none.

REFERENCES

- [1] Aslan K, Gunbey HP, Tomak L, Incesu L. The diagnostic value of using combined mr diffusion tensor imaging parameters to differentiate between low- and high- grade meningioma. *Br J Radiol* 2018; 91(1088): 20180088. <http://dx.doi.org/10.1259/bjr.20180088>
- [2] Nguyen EK, Nguyen TK, Boldt G, Louie AV, Bauman GS. Hypofractionated stereotactic radiotherapy for intracranial meningioma: A systematic review. *Neurooncol Pract* 2019; 6(5): 346-53. <http://dx.doi.org/10.1093/nop/npy053>
- [3] Fatima N, Meola A, Pollom E, Chaudhary N, Soltys S, Chang SD. Stereotactic radiosurgery in large intracranial meningiomas: A systematic review. *World Neurosurg* 2019; 129: 269-75. <http://dx.doi.org/10.1016/j.wneu.2019.06.064>
- [4] Speckter H, Bido J, Hernandez G, et al. Prognostic value of diffusion tensor imaging parameters for Gamma Knife radiosurgery in meningiomas. *J Neurosurg* 2016; 125 (Suppl. 1): 83-8. <http://dx.doi.org/10.3171/2016.7.GKS161455> PMID: 27903190
- [5] Ding D, Xu Z, McNeill IT, Yen CP, Sheehan JP. Radiosurgery for parasagittal and parafalcine meningiomas. *J Neurosurg* 2013; 119(4): 871-7. <http://dx.doi.org/10.3171/2013.6.JNS13110> PMID: 23930861
- [6] Louis DN, Perry A, Reifenberger G, et al. The 2016 world health organization classification of tumors of the central nervous system: A summary. *Acta Neuropathol* 2016; 131: 803-20. <http://dx.doi.org/10.1007/s00401-016-1545-1>
- [7] Mansouri A, Larjani S, Klironomos G, et al. Predictors of response to Gamma Knife radiosurgery for intracranial meningiomas. *J Neurosurg* 2015; 123: 1294-300. <http://dx.doi.org/10.3171/2014.12.JNS141687>
- [8] Santacrose A, Walier M, Régis J, et al. Long-term tumor control of benign intracranial meningiomas after radiosurgery in a series of 4565 patients. *Neurosurgery* 2012; 70: 32-9. <http://dx.doi.org/10.1227/NEU.0b013e31822d408a>
- [9] Sheehan JP, Starke RM, Kano H, et al. Gamma Knife radiosurgery for posterior fossa meningiomas: A multicenter study. *J Neurosurg* 2015; 122: 1479-89. <http://dx.doi.org/10.3171/2014.10.JNS14139>
- [10] Sheehan JP, Starke RM, Kano H, et al. Gamma Knife radiosurgery for sellar and parasellar meningiomas: A multicenter study. *J Neurosurg* 2014; 120: 1268-77. <http://dx.doi.org/10.3171/2014.2.JNS13139>
- [11] Astner ST, Theodorou M, Dobrei-Ciuchendea M, et al. Tumor shrinkage assessed by volumetric MRI in the long-term follow-up after stereotactic radiotherapy of meningiomas. *Strahlenther Onkol* 2010; 186: 423-9. <http://dx.doi.org/10.1007/s00066-010-2138-x>
- [12] Jolapara M, Kesavadas C, Radhakrishnan VV, et al. Role of diffusion tensor imaging in differentiating subtypes of meningiomas. *J Neuroradiol* 2010; 37: 277-83. <http://dx.doi.org/10.1016/j.neurad.2010.03.001>
- [13] Toh CH, Castillo M, Wong AM, et al. Differentiation between classic and atypical meningiomas with use of diffusion tensor imaging *AJNR Am J Neuroradiol* 2008; 29: 1630-5. <http://dx.doi.org/10.3174/ajnr.A1170>
- [14] Wang S, Kim S, Zhang Y, et al. Determination of grade and subtype of meningiomas by using histogram analysis of diffusion-tensor imaging metrics. *Radiology* 2012; 262: 584-92. <http://dx.doi.org/10.1148/radiol.11110576>
- [15] Kashimura H, Inoue T, Ogasawara K, et al. Prediction of meningioma consistency using fractional anisotropy value measured by magnetic resonance imaging. *J Neurosurg* 2007; 107: 784-7. <http://dx.doi.org/10.3171/JNS-07/10/0784>
- [16] Tropine A, Dellani PD, Glaser M, et al. Differentiation of fibroblastic meningiomas from other benign subtypes using diffusion tensor imaging. *J Magn Reson Imaging* 2007; 25: 703-8. <http://dx.doi.org/10.1002/jmri.20887>
- [17] Youlin G, Dong L, Zhiyuan Z, et al. Gamma Knife radiosurgery for intracranial benign meningiomas: follow-up outcome in 130 patients. *Neurosurg Focus* 2019; 46(6): E7. <http://dx.doi.org/10.3171/2019.3.FOCUS1956>
- [18] Specter H, Bido J, Hernandez G, et al. Pretreatment texture analysis of routine MR images and shape analysis of the diffusion tensor for prediction of volumetric response after radiosurgery for meningioma. *J Neurosurg* 2018; 129: 31-7. <http://dx.doi.org/10.3171/2018.7.GKS181327>
- [19] Di Franco R, Borzillo V, Ravo V, et al. Radiosurgery and stereotactic radiotherapy with cyberknife system for meningioma treatment. *Neuroradiol J* 2018; 31: 18-26. <http://dx.doi.org/10.1177/1971400917744885>
- [20] Fatima N, Meola A, Pollom EL, Soltys SG, Chang SD. Stereotactic radiosurgery versus stereotactic radiotherapy in the management of intracranial meningiomas: A systematic review and meta-analysis. *Neurosurg Focus* 2019; 46: 6-E2. <http://dx.doi.org/10.3171/2019.3.FOCUS1970>
- [21] Flannery T, Poots J. Gamma knife radiosurgery for Meningioma. *Prog Neurol Surg* 2019; 34: 91-9. <http://dx.doi.org/10.1159/000493054>
- [22] Pinzi V, Fariselli L, Marchetti M, Scorsetti M, Navarra P. Stereotactic radiotherapy for parasagittal and parafalcine meningiomas: patient selection and special considerations. *Cancer Manag Res* 2019; 11: 10051-60. <http://dx.doi.org/10.2147/CMAR.S187371>
- [23] Huang RY, Bi WL, Weller M, et al. Proposed response assessment and endpoints for meningioma clinical trials: Report from the Response Assessment in Neuro-Oncology Working Group. *Neuro-oncol* 2019; 21(1): 26-36. <http://dx.doi.org/10.1093/neuonc/noy137> PMID: 30137421
- [24] Kondziolka D, Shin SM, Brunswick A, Kim I, Silverman JS. The biology of radiosurgery and its clinical applications for brain tumours. *Neuro Oncol* 2015; 17: 29-44. <http://dx.doi.org/10.1093/neuonc/nou284>
- [25] Romani R, Tang WJ, Mao Y, et al. Diffusion tensor magnetic resonance imaging for predicting the consistency of intracranial meningiomas. *Acta Neurochir (Wien)* 2014; 56: 1837-45. <http://dx.doi.org/10.1007/s00701-014-2149-y>