

Case report

Management of a Jehovah's Witness patient with ANCA-Associated Vasculitis Following Pfizer-BioNTech COVID-19 Vaccine

*Wilhelm Herbst^{id}, Graham Paget^{id}

Department of Internal Medicine, Division of Nephrology, School of Clinical Medicine, Faculty of Health Sciences, University of the Witwatersrand, Johannesburg, South Africa

*Correspondence to: wherbst.herbst@gmail.com

Abstract: Anti-neutrophil cytoplasmic antibody (ANCA) vasculitis is defined as a systemic autoimmune disease limited to small calibre vasculature, associated with the presence of myeloperoxidase or proteinase 3. After receiving Pfizer BioNTech COVID-19 vaccine a 77-year-old woman of Jehovah's Witness faith presented with renal limited anti-MPO-AAV with underlying iron deficiency anaemia. Treatment was initiated with corticosteroids, iron repletion, Epoetin-beta, renal replacement therapy, plasma exchange with albumin, and cyclophosphamide with successful clearance of ANCA vasculitis. Although Jehovah's Witnesses may refuse transfusion of cellular blood products, they accept and expect alternative effective medical care.

CASE REPORT

Management of a Jehovah's Witness patient, who declined blood products with Anti neutrophil cytoplasmic antibody associated vasculitis (AAV) following Pfizer BioNtech COVID-19 Vaccine.

BACKGROUND

A temporal association between the influenza vaccine and new onset AAV (1) has been described, with reported occurrence following COVID-19 vaccination.(2)

AAV is defined as a systemic autoimmune disease exemplified by necrotizing inflammation limited to a small calibre vasculature, and is in most instances associated with the presence of myeloperoxidase (MPO-ANCA) or proteinase 3 (PR3-ANCA). AAV can be further classified into granulomatosis with polyangiitis (GPA), microscopic polyangiitis (MPA), and eosinophilic granulomatosis with polyangiitis (EGPA).(1)

ANCAs are autoantibodies targeted to the cytoplasmic granules of granulocytes, specifically neutrophils and monocytes. They can be identified with immunofluorescence staining. If the stain reacts with the cytoplasm of the granulocyte, it is defined as cytoplasmic antineutrophilic cytoplasmic antibody (C-ANCA) and if the stain reacts with perinuclear granules of the cell, it is defined as a perinuclear antineutrophilic cytoplasmic antibody (P-ANCA). The specific target antigen for P-ANCA is myeloperoxidase, whereas for C-ANCA it is proteinase 3.(1)

We report a case of new onset renal-limited anti-MPO AAV following a recent COVID-19 vaccination, in a Jehovah's witness patient with anaemia.

CASE PRESENTATION

A 77-year-old female Portuguese citizen of Jehovah's witness faith, with a past medical history of hypertension and hypothyroidism received her first dose of Pfizer BioNtech COVID-19 vaccine on 30 June 2021 after which she developed malaise, fatigue and diarrhoea. Medical care was not sought at the time as these symptoms were mild. She received the second dose of the vaccine on 11 August 2021, after which she developed bipedal pitting oedema, facial swelling and dyspnoea.

At the time of presentation (30 August 2021), laboratory assessment revealed haemoglobin level of 7.5 g/dL, serum creatinine level 650 umol/L (normal 49–90 umol/L), and 3363 mg/dL of proteinuria. The real-time polymerase chain reaction for SARS-CoV-2 was negative and there was no previous documented history of COVID-19. Further work-up revealed an elevated P-ANCA titre >1:2560 (normal <1:20) and a quantitative myeloperoxidase value of 62.0 IU/ml (normal 0.0–3.4 IU/ml). Of significance, the patient had biochemically confirmed iron deficiency as evidenced by Iron 2.1 umol/L (normal 9.0–30.4 umol/L), Transferrin 1.6 g/L (normal 2.5–3.8 g/L) and transferrin saturation of 5% (normal 15%–50%). Other serological tests, including quantitative PR3 and C-ANCA were negative. There was no evidence of alveolar haemorrhage, as the patient did not have haemoptysis and the chest X ray was unremarkable; CT of the lungs was not performed. A diagnosis of renal limited anti-MPO-AAV with iron deficiency anaemia was made, however a renal biopsy was not performed as it was deemed not safe to do.

Treatment was initiated with hydrocortisone 50 mg 8 hourly for 6 days followed by prednisone 1 mg/kg daily.

Iron stores were repleted with intravenous iron sucrose 100 mg daily for 5 days, after which the anaemia was further treated with Epoetin-beta (Recormon, Roche, Country) 450 IU/kg per week divided into daily doses for the duration of hospital stay. Renal replacement therapy was also provided on days 3, 8, and 9 in the form of slow low efficiency dialysis. The patient, her family, and her religious counsel were informed of her illness and the risk of mortality should treatment be delayed. The importance of plasma exchange was emphasised, however the patient made the informed decision that she would not accept plasma or cellular blood products, but was willing to accept alternative treatment options. Following further discussion with the patient and the family, they agreed to plasma exchange with albumin as an alternative to blood products. Centrifugal plasma exchange had to be withheld on day 3 after haemoglobin decreased to 5.7 g/dL, for fear of haemodynamic instability. Following pharmacological treatment with iron supplementation and erythropoietin the haemoglobin increased to 8.1 g/dL on day 14, plasma exchange could be reinitiated for another 5 days on days 15-20.

The patient additionally received two cycles of cyclophosphamide at a dose of 500 mg intravenously on days 20 and 34, respectively, and remission was achieved with serological evidence of negative P-ANCA and MPO levels. The patient was discharged with a glomerular filtration rate of 12 ml/min; however, she demised at home one month later.

The selection criteria for government funded renal replacement therapy in South Africa require rationing governed by distributive justice in the selection of suitable candidates, and consequently would have excluded this patient from the programme.(3) This is attributed to the patient's frailty, advanced age, and foreign nationality. In the under-resourced public healthcare sector in South Africa, there is insufficient capacity to provide universal chronic renal replacement therapy.(3)

DISCUSSION AND CONCLUSION

Vaccines have proven to be safe and effective at preventing life-threatening COVID-19 disease, and adverse events are mostly mild and self-limiting. Despite reports of more severe systemic adverse events, whether autoimmune diseases can be triggered following vaccination remains contested among various expert panels.

The aetiology of AAV is largely unknown. Environmental factors including silica exposure have been observed to play a proposed role in the pathogenesis, but the exact mechanism is still unclear. Given the pauci-immune nature of AAV, it is conceivable that autoimmune diseases, in genetically predisposed individuals, can be provoked by certain immune mechanisms, such as molecular mimicry, polyclonal activation, or a transient systemic proinflammatory cytokine mediated response, which may explain this temporal relationship.(2)

In patients who present with glomerulonephritis, initial therapy largely involves the use of corticosteroids in addition to cyclophosphamide which has been proven to achieve remission in close to 90% of patients. Additionally plasma exchange is recommended in severe disease. Plasma exchange has been associated with a favourable outcome in cases with pulmonary haemorrhage and severe kidney disease, especially in patients presenting with a serum creatinine value of >500 mmol/L.(1)

There is a high prevalence of anaemia among patients with renal AAV, which could be multifactorial, related to renal failure and chronic disease. The severity of the anaemia has been shown to correlate with the degree of renal injury and prognosis.(4)

The Watchtower and Awake, known as the Jehovah's Witnesses official biblical journal, remarked on the sanctity of blood in December 1927 for the first time. *The Watchtower* subsequently released a report in December 1944, asserting that a devoted member "was forbidden to eat or drink blood, whether by transfusion or by mouth". This particular proscription made on religious grounds based on biblical passages from the Old and New Testaments (i.e. Leviticus 17:10-16 and Acts 15:19-29, respectively), applies to both cellular and acellular blood constituents, including plasma, red blood cells, granulocytes, platelets, and whole blood.(5)

Although Jehovah's Witnesses may refuse transfusion of cellular blood products, they accept and expect alternative effective medical care. In 2001, *The Watch Tower and Awake* published that acceptance of "fractions of any primary blood component (cellular blood products and plasma)" must be "conscientiously decided" by each individual.(5) To that effect, every Jehovah's Witness patient should be asked about their personal understanding of what represents blood products.

Alternatives to blood products in patients who are profoundly anaemic include iron replacement and erythropoiesis-stimulating agents, which have been shown to be effective over the short term and deemed acceptable to the majority of Jehovah's Witnesses. Additionally, a bovine derived haemoglobin based oxygen carrier-201 (HBOC – 201) solution known as Hemopure, is registered for routine use in South Africa for the treatment of anaemia related largely to surgical causes, however, successful treatments for medical anaemias has also been widely described.(6)

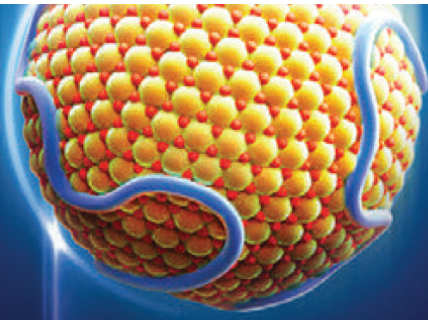
Our case is not only unique in describing the uncommon occurrence of AAV following COVID-19 vaccination, but also describes an example of adjusting standard treatment to accommodate a patient's religious views. These situations may create daunting medical and ethical dilemmas, it is therefore important to provide efficacious alternative modalities for patients who may refuse conventional regimens due to religious beliefs. This can be achieved by having an individualized approach in the patient's best interest.

AAV is a nephrological emergency and the first 2 weeks of the illness are critical for recovery when intensive treatment with corticosteroids, cyclophosphamide and possibly plasma

exchange are instituted to try and avert renal fibrosis. The severe anaemia prevented the patient having a kidney biopsy (which would have been useful for prognosis) and caused delays in continuing plasma exchange. So, while treatment alternatives are feasible for religious reasons, they are not as effective and contributed to the patient's eventual outcome.

REFERENCES

1. Dousdampanis P, Assimakopoulos SF, Trigka K. Microscopic polyangiitis: from pathogenesis to treatment. *Urol Nephrol Open Access J.* 2017; 5(2):00167.
2. Wu H, Kalra P, Chinnadurai R. New-onset and relapsed kidney histopathology following COVID-19 vaccination: a systematic review. *Vaccines (Basel).* 2021; 9(11):1252.
3. Moosa M, Wearne N. Invited commentary should we be rationing dialysis in South Africa in the 21st century? *Perit Dial Int.* 2018; 38(2):84–88.
4. Kawamura T, Usui J, Kaneko S, et al. Anaemia is an essential complication of ANCA-associated renal vasculitis: a single center cohort study. *BMC Nephrol.* 2017; 18(1):337.
5. Scharman C, Burger D, Shatzel J, Kim E, DeLoughery T. Treatment of individuals who cannot receive blood products for religious or other reasons. *Am J Hematol.* 2017; 92(12):1370–1381.
6. DeLoughery T. Transfusion replacement strategies in Jehovah's Witnesses and others who decline blood products. *Clin Adv Hematol Oncol.* 2020; 18(12):826–836.



AMGEN[®]

Cardiovascular

Amgen brings 35 years of leadership in biologics to the challenges of cardiovascular disease, specifically in areas of unmet patient needs.¹

1 A PG 1



MORE THAN
35 YEARS
BIOTECHNOLOGY
BY AMGEN[®]

Reference: 1. The Amgen Story. Unlocking the Potential of Biology for Patients. viewed on 22 June 2017 from <http://www.agmenhistory.com>

Amgen South Africa (Pty) Ltd., Co. Reg. No.: 2011/112148/07 Building D, Ballyoaks Office Park, 35 Ballyclare Drive, Bryanston Ext. 7, 2021.
Tel: 011 100 5300 Fax: 011 100 5301 Adverse Event Reporting Fax: 0800 166 513

PR-REP ZAF-000073