

Coil embolization of an aberrant posterior tibial artery pseudoaneurysm after total knee arthroplasty

Zachary J. Wanken, MD, J. Aaron Barnes, MD, Anna J. Eppolito, MS, RVT, Robert M. Zwolak, MD, PhD, and Bjoern D. Suckow, MD, MS, Lebanon, NH

ABSTRACT

Arterial injury is a recognized but rare complication of total knee arthroplasty. These injuries, however, can be exceptionally devastating and potentially result in limb loss. Presentation may be delayed with symptoms associated with mass effect rather than with ischemia. We describe treatment of a patient with presentation delayed 2 weeks. In addition, the patient's arterial branch pattern demonstrated aberrant anatomy with high takeoff of the posterior tibial artery. This patient was successfully treated with transcatheter coil embolization. The current treatment options and published literature are reviewed. (*J Vasc Surg Cases and Innovative Techniques* 2019;5:497-500.)

Keywords: Pseudoaneurysm; Iatrogenic injury; Coil embolization

Arterial injury is a recognized but rare complication of total knee arthroplasty (TKA) with a reported incidence of 0.03% to 0.2%.^{1,2} Direct arterial injury from instrumentation, such as laceration, transection, avulsion, compression, or dissection, is the most common mechanism of injury and can lead to subsequent thrombosis and acute limb ischemia.³ Rarely, injury may result in pseudoaneurysm formation with associated mass effect symptoms rather than ischemia.⁴ Identification of nonischemic injuries can be more difficult with significant delay several days beyond the index operation.² Although rare, a popliteal pseudoaneurysm in the setting of TKA can be devastating. Potential complications include nerve injury and venous thrombosis from compression or even amputation.³

A wide variety of treatment options have been described for traumatic lower extremity pseudoaneurysms in relation to orthopedic surgery. The traditional option is open surgical decompression with primary repair of the involved artery.⁵ Less invasive techniques from simple thrombin injection⁶ to endovascular stent graft exclusion^{7,8} and coil embolization^{9,10} are also described. We report a case in which a patient with previously unknown, aberrant, high-takeoff posterior tibial (PT) artery anatomy underwent TKA and a traumatic pseudoaneurysm arising from the aberrant PT artery developed. This was successfully treated with coil embolization. Consent

for the publication of this report was obtained from the patient.

CASE REPORT

A 76-year-old woman presented to the emergency department 2 weeks after elective right TKA for degenerative osteoarthritis. The TKA had been performed without the use of a tourniquet, and the patient recovered from surgery following the usual pathway with no identified concerns of arterial injury, compartment syndrome, or other complication. Her chief complaint at the time of presentation to the emergency department was progressive pain in the right ankle and shin. She was taking warfarin for deep venous thrombosis prophylaxis in the postoperative period, and international normalized ratio on presentation was 2.5. A right lower extremity venous duplex ultrasound examination was performed and negative for deep venous thrombosis. However, a 3.7-cm pseudoaneurysm was noted as an incidental finding in the popliteal fossa (Fig 1). On physical examination at the time of initial vascular surgery consultation, the patient had a palpable femoral pulse, prominent popliteal pulse, and palpable dorsalis pedis pulse. The PT pulse was not palpable, but Doppler signal was present. All lower leg compartments were soft to palpation, and there was mild swelling of the calf. The motor and sensory functions of the foot were normal. The patient was admitted to the hospital, warfarin was held, and vitamin K was administered for reversal of anticoagulation. A computed tomography angiogram of the right leg was obtained, but scatter artifact from the prosthesis made interpretation difficult. It did delineate an aberrant course of the PT artery with a high takeoff. Neither the duplex ultrasound scan nor the computed tomography scan could delineate a clear source of the pseudoaneurysm but did confirm patency of the popliteal artery proximal and distal to the popliteal fossa. The following day, the patient was taken for formal angiography to better characterize the anatomy.

Right leg angiography through retrograde, contralateral femoral artery access demonstrated patent superficial femoral and popliteal arteries as well as aberrant anatomy with high takeoff of the PT artery. The popliteal artery divided into the

From the Section of Vascular Surgery, Dartmouth-Hitchcock Medical Center.

Author conflict of interest: none.

Correspondence: Zachary J. Wanken, MD, Section of Vascular Surgery, Dartmouth-Hitchcock Medical Center, One Medical Center Dr, Lebanon, NH 03766 (e-mail: zwanken@gmail.com).

The editors and reviewers of this article have no relevant financial relationships to disclose per the Journal policy that requires reviewers to decline review of any manuscript for which they may have a conflict of interest.

2468-4287

© 2019 The Authors. Published by Elsevier Inc. on behalf of Society for Vascular Surgery. This is an open access article under the CC BY-NC-ND license (<http://creativecommons.org/licenses/by-nc-nd/4.0/>).

<https://doi.org/10.1016/j.jvscit.2019.08.007>

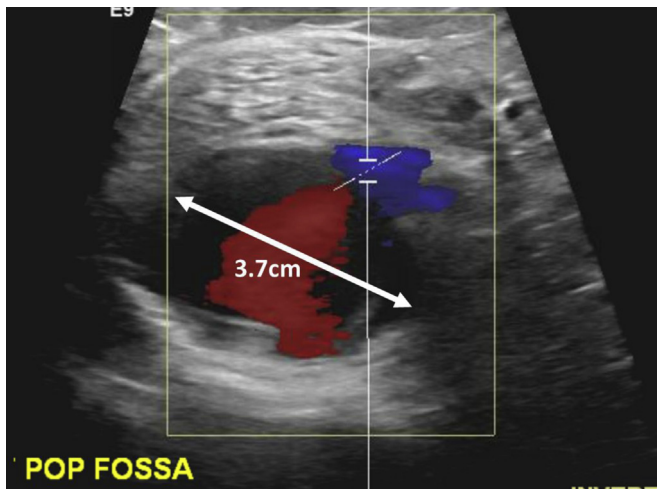


Fig 1. Duplex ultrasound examination was performed to evaluate for venous thrombosis. A pseudoaneurysm of 3.7 cm in diameter was noted in the popliteal fossa as an incidental finding.

anterior tibial (AT) and PT arteries at the level of a normal AT origin (Fig 2). The PT artery was catheterized with a VI8 wire (Boston Scientific, Marlborough, Mass) and Renegade STC 18 catheter (Boston Scientific). A lateral arteriogram was then obtained with selection of the PT artery, shown to directly feed the pseudoaneurysm. There was clear damage to the PT artery without any distal flow, suggesting likely transection or thrombosis of the distal artery rather than vasospasm, given the duration of time after the injury (Fig 3). The area of injury was discrete from the aberrant branch point. Coil embolization was then performed with three 0.018-inch Interlock coils (Boston Scientific), showing complete exclusion of the pseudoaneurysm as well as the inflow and outflow portions of the PT artery (Fig 4). Distal perfusion of the leg remained intact on completion angiography with robust flow through the AT and peroneal arteries. The patient recovered well postoperatively without nerve or venous damage from local compression. Her calf cramping resolved as the pseudoaneurysm shrunk and the local mass effect on the nerve was alleviated. Thrombosis of the pseudoaneurysm was confirmed with duplex ultrasound on postprocedure day 3. At 1-month follow-up, ankle-brachial indices were completely normal with an index of 1.1 and triphasic waveform at both dorsalis pedis and PT locations. The patient maintained a palpable dorsalis pedis pulse without any symptoms of ischemia.

DISCUSSION

TKA is a common procedure with approximately 500,000 of these operations performed yearly in the United States.¹¹ Arterial injury during this operation is a known but rare complication with an estimated event rate of 0.03% to 0.2%.^{1,12} Injury is most often due to direct trauma to the artery, although thermal injury can occur as well. Risk factors for arterial injury during TKA include peripheral artery disease, popliteal aneurysm, and

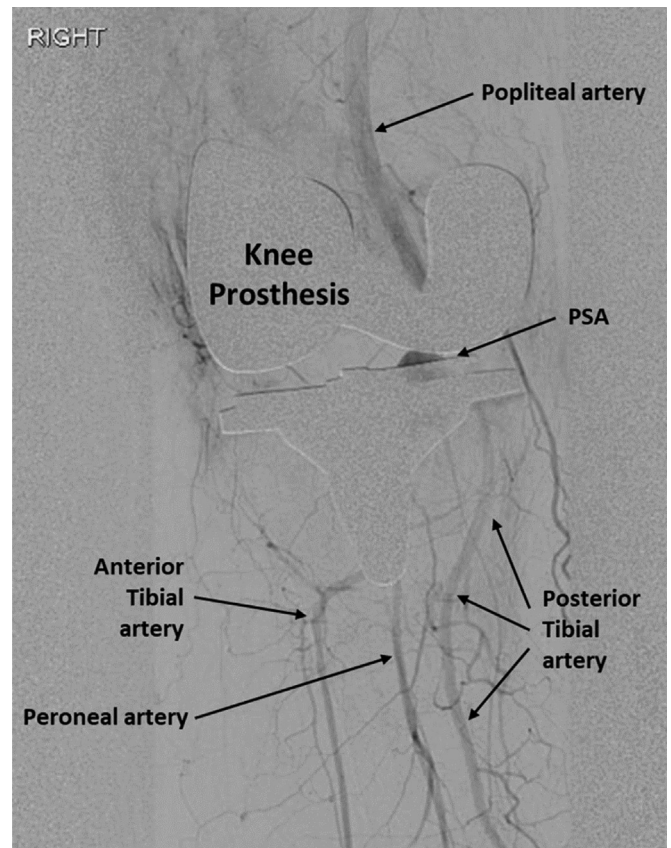


Fig 2. Anteroposterior arteriogram of the right knee area showing the pseudoaneurysm (PSA) behind the knee prosthesis.

revision TKA in which the anatomy is distorted because of the scarred operative field.¹³ Several sequelae can be seen as a result of arterial injury. Acute limb ischemia from dissection, transection, or avulsion of the artery is most common, with pseudoaneurysm formation seen less frequently.² As in this case, pseudoaneurysm can be manifested in a delayed fashion, with gradual symptom onset due to mass effect rather than acute ischemia.⁴ The popliteal artery is the most common location of injury, although pseudoaneurysm of geniculate branches has also been described.⁹ Tibial arteries are usually spared owing to their location distal to the surgical field. Injury associated with aberrant branch anatomy is therefore exceedingly uncommon.

Multiple treatment options have been described for traumatic pseudoaneurysm. The most invasive option is open, direct surgical repair of the artery with decompression of the associated hematoma.⁵ This is certainly necessary in the presence of a hard indication for surgical decompression, such as compartment syndrome.¹⁴ However, minimally invasive treatment options are available and appealing because of a lower potential for wound complications. Thrombin injection of pseudoaneurysm is one of these options and has been described

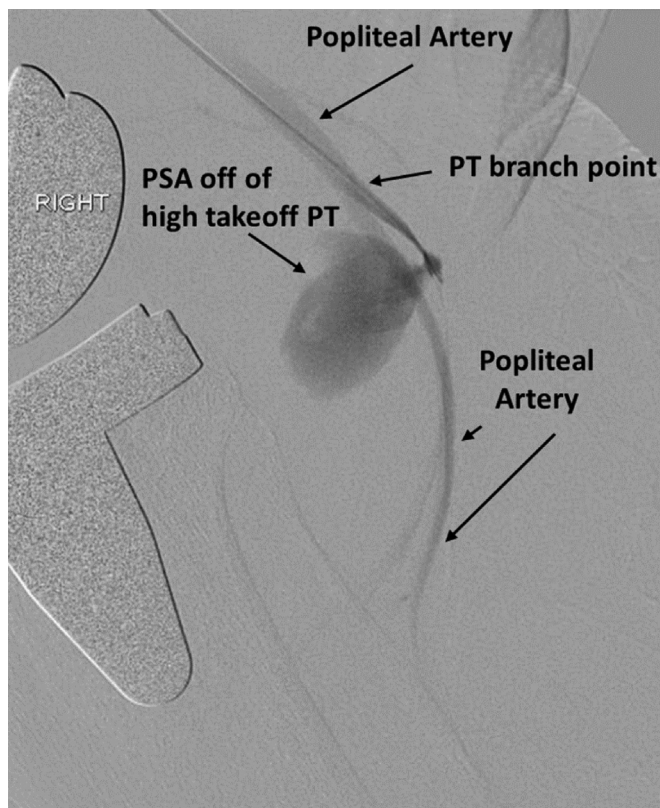


Fig 3. Lateral arteriogram demonstrating the high branch point of the posterior tibial (PT) artery and origin of the pseudoaneurysm (PSA).

extensively at the site of the common femoral artery. Anatomic factors, such as the width and length of the pseudoaneurysm neck, are important considerations with regard to embolic and thrombotic risk.¹⁵ Stent graft exclusion has also been described and is well suited for larger arteries. However, this option requires shelf stock of appropriately sized devices. In our case, a tibial artery was traumatized, and this is generally not amenable to stent grafting for pseudoaneurysm exclusion because of small vessel diameter, which results in poor stent graft patency over time. In contrast, ligation of tibial arteries is well described in open surgical management of extremity trauma and depends on robust collateralization.¹⁶ In our case, the patient's AT and peroneal arteries were widely patent, thus allowing coil embolization to be employed as a minimally invasive means to the same end. Ultimately, we elected to pursue embolization of the damaged artery.

Coil embolization is widely used in various areas of interventional care. This technique has been described in arterial injuries after orthopedic interventions. Specifically after TKA, coil embolization has been described in a number of small case series.^{3,9,10} The prevalence of aberrant tibial branch anatomy is estimated at around 10%. High takeoff of the AT artery and trifurcation

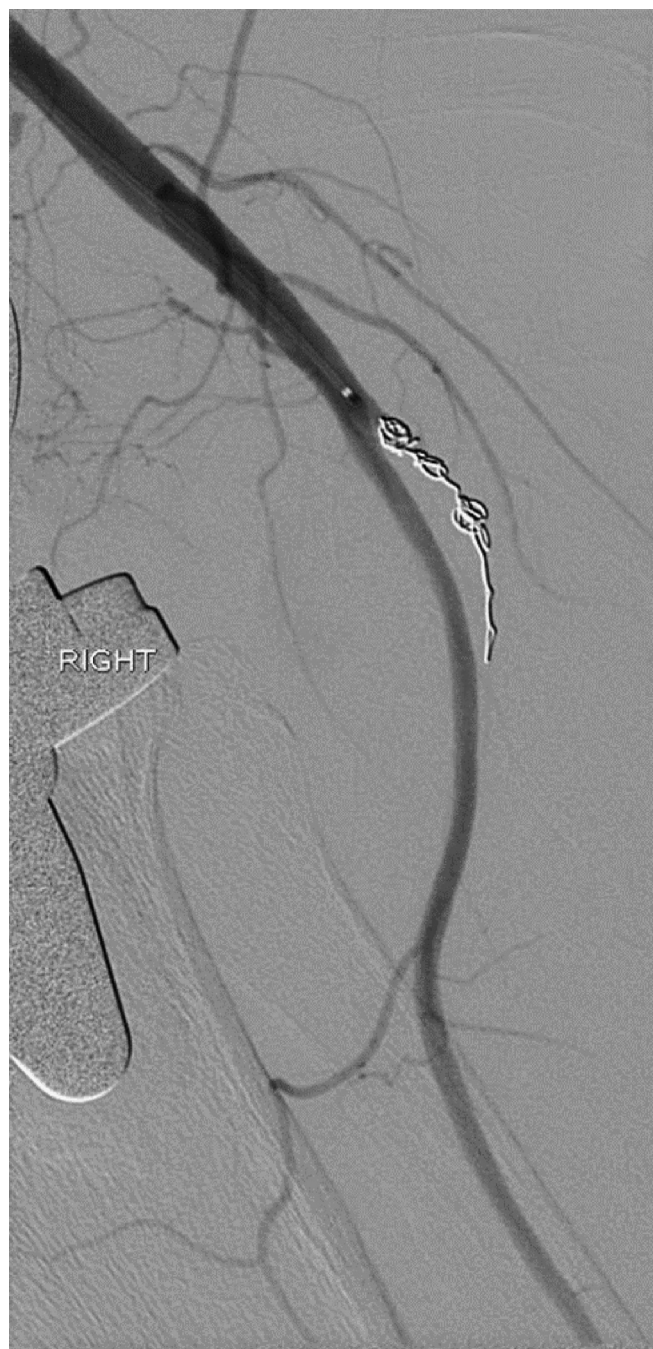

Fig 4. Completion arteriogram demonstrates complete exclusion of pseudoaneurysm after coil placement with preservation of robust anterior tibial (AT) and peroneal runoff.

(common origin of AT, PT, and peroneal arteries) branch patterns are the most common variants.¹⁷ High takeoff of the PT artery is an uncommon variant. Our case supports previous findings that embolization or ligation of an individual tibial artery for injury is safe and effective in the setting of otherwise patent tibial runoff.¹⁸ Furthermore, our case supports the feasibility of the technique with aberrant branch anatomy.

Last, two techniques developed for treatment of intracranial aneurysms are worth discussing. Stent-assisted coil embolization is performed by deploying coils behind a bare-metal stent that spans the aneurysm neck.¹⁹ Coils can be deployed either through the interstices of the stent or through a catheter positioned alongside the stent. Stent-assisted coil embolization is primarily used for cerebral aneurysms, although it has also been described for pseudoaneurysm of the aorta that was not amenable to conventional repair techniques.²⁰ The Pipeline Embolization Device and updated Pipeline Flex (Medtronic Neurovascular Inc, Irvine, Calif) are flow diversion devices that promote neoendothelial growth across the aneurysm neck for exclusion.²¹ Flow diversion technology is most useful in broad-neck aneurysms that are not amenable to coil embolization. More than 90% of patients treated with flow diversion devices have successful aneurysm exclusion at 6 months. These techniques are infrequently used in the peripheral artery system but are useful to have in the overall armamentarium of vascular surgery.

CONCLUSIONS

Arterial injury is a rare complication of TKA. Prompt identification is key to avoidance of detrimental sequelae. Coil embolization can be a safe and effective treatment of isolated tibial artery injury.

REFERENCES

- O'Connor JV, Stocks G, Crabtree JD Jr, Galasso P, Wallsh E. Popliteal pseudoaneurysm following total knee arthroplasty. *J Arthroplasty* 1998;13:830-2.
- Calligaro KD, Dougherty MJ, Ryan S, Booth RE. Acute arterial complications associated with total hip and knee arthroplasty. *J Vasc Surg* 2003;38:1170-7.
- Padegimas EM, Levicoff EA, McGinley AD, Sharkey PF, Good RP. Vascular complications after total knee arthroplasty—a single institutional experience. *J Arthroplasty* 2016;31:1583-8.
- Agarwala SR, Mohrir GS, Dotivala SJ. Posttraumatic pseudoaneurysm of popliteal artery following total knee arthroplasty. *Indian J Orthop* 2013;47:101-3.
- Langkamer VG. Local vascular complications after knee replacement: a review with illustrative case reports. *Knee* 2001;8:259-64.
- Hanson CG, Hanson LF. Non-invasive repair of an iatrogenic tibial artery branch pseudoaneurysm after intramedullary nailing. *J Clin Orthop Trauma* 2017;8(Suppl 2):S49-51.
- de Troia A, Biasi L, Iazzolino L, Azzarone M, Tecchio T, Rossi C, et al. Endovascular stent grafting of a posterior tibial artery pseudoaneurysm secondary to penetrating trauma: case report and review of the literature. *Ann Vasc Surg* 2014;28:1789.e13-7.
- Jones A, Kumar S. Successful stenting of iatrogenic anterior tibial artery pseudoaneurysm. *EJVES Short Rep* 2016;30:4-6.
- Carlin RE, Papenhausen M, Farber MA, Ronningen E, Mauro MA, Marston WA, et al. Sural artery pseudoaneurysms after knee arthroscopy: treatment with transcatheter embolization. *J Vasc Surg* 2001;33:170-3.
- Ibrahim M, Booth RE Jr, Clark TW. Embolization of traumatic pseudoaneurysms after total knee arthroplasty. *J Arthroplasty* 2004;19:123-8.
- Cram P, Lu X, Kates SL, Singh JA, Li Y, Wolf BR. Total knee arthroplasty volume, utilization, and outcomes among Medicare beneficiaries, 1991-2010. *JAMA* 2012;308:1227-36.
- Ko LJ, DeHart ML, Yoo JU, Huff TW. Popliteal artery injury associated with total knee arthroplasty: trends, costs and risk factors. *J Arthroplasty* 2014;29:1181-4.
- Butt U, Samuel R, Sahu A, Butt IS, Johnson DS, Turner PG. Arterial injury in total knee arthroplasty. *J Arthroplasty* 2010;25:1311-8.
- Pinheiro AA, Marques PM, Sá PM, Oliveira CF, da Silva BP, de Sousa CM. Compartment syndrome after total knee arthroplasty: regarding a clinical case. *Rev Bras Ortop* 2015;50:478-81.
- Dzijan-Horn M, Langwieser N, Groha P, Bradaric C, Linhardt M, Bottiger C, et al. Safety and efficacy of a potential treatment algorithm by using manual compression repair and ultrasound-guided thrombin injection for the management of iatrogenic femoral artery pseudoaneurysm in a large patient cohort. *Circ Cardiovasc Interv* 2014;7:207-15.
- Macedo FI, Sciarretta JD, Chausse S, Sleeman D, Pizano LR, Namias N. Vascular reconstruction is not warranted in most civilian traumatic shank vascular injuries. *Ann Vasc Surg* 2016;35:38-45.
- Kropman RH, Kiela G, Moll FL, de Vries JP. Variations in anatomy of the popliteal artery and its side branches. *Vasc Endovascular Surg* 2011;45:536-40.
- Singh D, Ferero A. Traumatic pseudoaneurysm of the posterior tibial artery treated by endovascular coil embolization. *Foot Ankle Spec* 2013;6:54-8.
- Phan K, Huo YR, Jia F, Phan S, Rao PJ, Mobbs RJ, et al. Meta-analysis of stent-assisted coiling versus coiling-only for the treatment of intracranial aneurysms. *J Clin Neurosci* 2016;31:15-22.
- Brechtel K, Bail D, Schwentner C, Heller S, Schmehl J, Goebel N, et al. Stent-assisted embolization as "bailout" option in aortic aneurysm. *J Vasc Interv Radiol* 2011;22:563-8.
- Martinez-Galdamez M, Lamin SM, Lagios KG, Liebig T, Ciceri EF, Chapot R, et al. Treatment of intracranial aneurysms using the Pipeline Flex Embolization Device with Shield Technology: angiographic and safety outcomes at 1-year follow-up. *J Neurointerv Surg* 2019;11:396-9.

Submitted Jun 29, 2019; accepted Aug 21, 2019.