

## COVID-19 pandemic: Pathophysiology and manifestations from the gastrointestinal tract

Michail Galanopoulos, Filippos Gkeros, Aris Doukatas, Grigorios Karianakis, Christos Pontas, Nikolaos Tsoukalas, Nikos Viazis, Christos Liatsos, Gerassimos J Mantzaris

**ORCID number:** Michail Galanopoulos [0000-0002-7544-2810](https://orcid.org/0000-0002-7544-2810); Filippos Gkeros [0000-0002-6240-5287](https://orcid.org/0000-0002-6240-5287); Aris Doukatas [0000-0001-8020-3331](https://orcid.org/0000-0001-8020-3331); Grigorios Karianakis [0000-0001-9380-4005](https://orcid.org/0000-0001-9380-4005); Christos Pontas [0000-0001-9282-9788](https://orcid.org/0000-0001-9282-9788); Nikolaos Tsoukalas [0000-0002-1455-1503](https://orcid.org/0000-0002-1455-1503); Nikos Viazis [0000-0002-0918-1587](https://orcid.org/0000-0002-0918-1587); Christos Liatsos [0000-0001-8025-0808](https://orcid.org/0000-0001-8025-0808); Gerassimos J Mantzaris [0000-0002-5302-5450](https://orcid.org/0000-0002-5302-5450).

### Author contributions:

Galanopoulos M designed the review; Galanopoulos M, Gkeros F, Doukatas A, Karianakis G and Pontas C analyzed and interpreted the data; Tsoukalas N, Viazis N and Liatsos C drafted the manuscript; Mantzaris GJ critically revised the paper.

### Conflict-of-interest statement:

There is no conflict of interest associated with any of the senior author or other coauthors contributed their efforts in this manuscript.

**Open-Access:** This article is an open-access article that was selected by an in-house editor and fully peer-reviewed by external reviewers. It is distributed in accordance with the Creative Commons Attribution NonCommercial (CC BY-NC 4.0) license, which permits others to

**Michail Galanopoulos, Christos Liatsos**, Department of Gastroenterology, 401 General Military Hospital of Athens, Athens 11525, Attiki, Greece

**Filippos Gkeros, Christos Pontas, Nikos Viazis, Gerassimos J Mantzaris**, Department of Gastroenterology, Evangelismos, Ophthalmiatreion Athinon and Polyclinic Hospitals, Athens 10676, Attiki, Greece

**Aris Doukatas, Grigorios Karianakis**, Medical Office of Hellenic Army General Staff, 401 General Military Hospital of Athens, Athens 11525, Attiki, Greece

**Nikolaos Tsoukalas**, Department of Oncology, 401 General Military Hospital of Athens, Athens 11525, Attiki, Greece

**Corresponding author:** Michail Galanopoulos, FEBG, MD, PhD, Doctor, Department of Gastroenterology, 401 General Military Hospital of Athens, 138 Mesogeion Avenue and Katechaki Street, Athens 11525, Attiki, Greece. [galanopoulosdr@gmail.com](mailto:galanopoulosdr@gmail.com)

### Abstract

The pandemic of coronavirus disease 2019 (COVID-19), caused by a newly identified  $\beta$ -coronavirus (SARS-CoV-2) has emerged as a dire health problem, causing a massive crisis for global health. Primary method of transmission was firstly thought to be animal to human transmission. However, it has been observed that the virus is transmitted from human to human via respiratory droplets. Interestingly, SARS-CoV-2 ribonucleic acid (RNA) has been isolated from patient stools, suggesting a possible gastrointestinal (GI) involvement. Most commonly reported clinical manifestations are fever, fatigue and dry cough. Interestingly, a small percentage of patients experience GI symptoms with the most common being anorexia, diarrhea, nausea and vomiting. The presence of viral RNA in stools is also common and fecal tests can be positive even after negative respiratory samples. The exact incidence of digestive symptoms is a matter of debate. The distribution of Angiotensin converting enzyme type 2 receptors in multiple organs in the body provides a possible explanation for the digestive symptoms' mechanism. Cases with solely GI symptoms have been reported in both adults and children. Viral RNA has also been detected in stool and blood samples, indicating the possibility of liver damage, which has been reported in COVID-19 patients. The presence of chronic liver disease appears to be a risk factor for severe complications and a poorer prognosis, however data

distribute, remix, adapt, build upon this work non-commercially, and license their derivative works on different terms, provided the original work is properly cited and the use is non-commercial. See: <http://creativecommons.org/licenses/by-nc/4.0/>

**Manuscript source:** Invited manuscript

**Received:** May 6, 2020

**Peer-review started:** May 6, 2020

**First decision:** May 26, 2020

**Revised:** June 2, 2020

**Accepted:** August 12, 2020

**Article in press:** August 12, 2020

**Published online:** August 21, 2020

**P-Reviewer:** Nagaya M

**S-Editor:** Zhang L

**L-Editor:** A

**P-Editor:** Wang LL



from these cases is lacking. The aim of this review is firstly, to briefly update what is known about the origin and the transmission of SARS-CoV-2, but mainly to focus on the manifestations of the GI tract and their pathophysiological background, so that physicians on the one hand, not to underestimate or disregard digestive symptoms due to the small number of patients exhibiting exclusively this symptomatology and on the other, to have SARS-CoV-2 on their mind when the “gastroenteritis” type symptoms predominate.

**Key words:** SARS-CoV-2; COVID-19; COVID-19 gastrointestinal manifestations; Gastrointestinal tract; COVID-19 on chronic liver diseases; ACE2 receptors and COVID-19; COVID-19 and gastrointestinal pathophysiology

©The Author(s) 2020. Published by Baishideng Publishing Group Inc. All rights reserved.

**Core tip:** Although respiratory transmission and symptoms are still the primary route and expression of coronavirus disease 2019 (COVID-19), the gastrointestinal system could be an alternative or additional way for COVID-19 to be transmitted and manifested, most likely due to the presence of Angiotensin converting enzyme type 2 receptors which are observed throughout its length. The main aim of this article is mainly to focus on the manifestations of the gastrointestinal tract and their pathophysiological background, so that physicians on the one hand, not to underestimate or disregard digestive symptoms due to the small number of patients exhibiting exclusively this symptomatology and, on the other, to have severe acute respiratory syndrome coronavirus 2 on their mind when the “gastroenteritis” type symptoms predominate.

**Citation:** Galanopoulos M, Gkeros F, Doukatas A, Karianakis G, Pontas C, Tsoukalas N, Viazis N, Liatsos C, Mantzaris GJ. COVID-19 pandemic: Pathophysiology and manifestations from the gastrointestinal tract. *World J Gastroenterol* 2020; 26(31): 4579-4588

**URL:** <https://www.wjgnet.com/1007-9327/full/v26/i31/4579.htm>

**DOI:** <https://dx.doi.org/10.3748/wjg.v26.i31.4579>

## INTRODUCTION

Novel viral diseases, such as the severe acute respiratory syndrome coronavirus (SARS-CoV) from 2002 to 2003, H1N1-influenza in 2009, and most recently, the Middle East respiratory syndrome coronavirus (MERS-CoV) posed serious threats to Health care systems<sup>[1]</sup>. In December 2019, a cluster of patients presenting with atypical pneumonia was reported by hospitals in Wuhan, China<sup>[2]</sup>. This was attributed to a newly identified  $\beta$ -coronavirus, which initially named 2019 novel coronavirus by WHO. The virus was afterwards renamed as severe acute respiratory syndrome coronavirus 2 (SARS-CoV-2) and the disease it caused named coronavirus disease 2019 (COVID-19)<sup>[3]</sup>. On January 30, 2020 WHO declared COVID-19 outbreak as a Public Health Emergency of International Concern<sup>[4,5]</sup>. Later, on March 11, 2020 the WHO declared this outbreak as Pandemic. Indeed, as of May 3, 2020, a total of 3349786 cases of COVID-19 have been confirmed globally causing 238628 deaths due to acute respiratory failure or other complications<sup>[6]</sup>. In contrast to SARS-CoV and MERS-CoV, the new virus is highly transmissible between individuals even during the pre-clinical phase of COVID-19.

Although the COVID-19 is typically an airborne infection, the massive expression of its receptor, Angiotensin converting enzyme type 2 (ACE2) throughout the gastrointestinal (GI) tract, the identification of virus in the surface epithelial cells of the stomach, small intestine and the colon, atypical presenting clinical symptoms from the GI tract, and prolonged shedding of virus or viral fragments in the stools of infected individuals have raised concerns whether the virus can be transmitted via an oral-fecal route as well as whether the GI tract serves as a repository for future re-infections<sup>[7-11]</sup>.

Taking all the above into consideration, the aim of this review is to update what is known on the origin and transmission of SARS-CoV-2, as well as to focus on the pathophysiology and clinical manifestations from the GI tract of COVID-19.

## ORIGIN OF SARS-COV-2

SARS-CoV-2 is a  $\beta$ -coronavirus, which is spherical positive-single stranded Ribonucleic acid (RNA) virus. Coronaviruses were identified in the 1960s and belong under the family of *Coronaviridae* (Figure 1). Members of this large family of viruses are able of causing enteric, neurological, hepatic and respiratory manifestations in various animal species, such as cattle, cats, camel and bats<sup>[1,12]</sup>. So far, seven Coronaviruses (HCoVs) capable of infecting humans and causing respiratory diseases have been identified including HCoV-OC43, HCoV-229E, HCoV-NL63 and HCoV-HKU1. The first two HCoVs, HCoV-OC43 and HCoV-229E are known since the 1960s<sup>[5,13]</sup>. The other two known betaCoVs, SARS-CoV and MERS-CoV are responsible for severe and potentially fatal respiratory tract infections, with the fatality rates being up to 10% and 35%, respectively (Table 1)<sup>[14,15]</sup>.

The genetic sequence analysis has shown that SARS-CoV-2 shares genetic identity of 79.0% and 51.8% to SARS-CoV and MERS-CoV, respectively, explaining the nomenclature of SARS-CoV-2. SARS-CoV-2 is also 96% identical to the entire genome of bat coronavirus. Based on the evolutionary analysis and virus genome sequencing, bat has been proposed as natural host of the virus<sup>[16,17]</sup>.

## TRANSMISSION

It has been proposed that COVID-19 originated in the Open Seafood market of Wuhan with bat being the presumed potential reservoir of SARS-CoV-2 and animal-to-human the primary mode of transmission (Figure 2). The virus was transmitted by intimate contact, primarily between patients or asymptomatic carriers with family members and friends<sup>[13,18]</sup>. Among patients who were not residents of Wuhan, 72.3% had a previous contact with people from Wuhan and 31.3% reported recent travel to Wuhan<sup>[19]</sup>. Of note, the incubation period of COVID-19 is usually 3-7 d, but it may extend up to 12.5 d, which renders tracing the asymptomatic carriers extremely difficult<sup>[18]</sup>. As a result, mathematical models have estimated that every seven days, this novel epidemic doubled in contrast with the basic reproduction number ( $R_0$ - $R_{naught}$ ), which is 2.2<sup>[4]</sup>.

COVID-19 is predominantly an airborne infection; transmission occurs via respiratory droplets and potentially *via* aerolised material<sup>[1]</sup>. Although an oral-fecal transmission has been proposed, the origin of the virus in the GI tract (swallowed saliva and/or rhino-pharyngeal exudate?) and the clinical significance of viral RNA shedding in the stools cannot *per se* confirm this mode of transmission because Reverse transcription-polymerase chain reaction (RT-PCR) may detect viral fragments and not the whole virus whereas stool cultures for the SARS-CoV-2 are still lacking or have low specificity<sup>[20]</sup>. Thus, more studies are needed to understand the mechanisms of transmission and incubation times, along with the duration of infectivity and clinical course.

## MAIN CLINICAL AND LABORATORY MANIFESTATIONS OF COVID-19

COVID-19 presents predominantly as a respiratory infection, with the most common symptoms being fever, fatigue and dry cough (Table 2)<sup>[19,21]</sup>. The median age of patients hospitalized for confirmed cases of COVID-19 is 56 years, with a slight male preponderance (54%)<sup>[21]</sup>.

In the early stages of the disease, lymphopenia appears to be the commonest laboratory finding (up to 80%), while the total white blood cell number varies<sup>[1,10,19,21]</sup>. This finding might suggest that SARS-CoV-2 acts on lymphocytes by inducing a cytokine storm in the body. Other studies support that SARS-CoV-2 consumes many immune cells and inhibits the body's normal function<sup>[10]</sup>. Persistent severe lymphopenia is associated with a grave outcome. Chest pain in association with a rise in troponin etc. indicates involvement of myocardium. As ACE2 is widely distributed in the human tissues, liver enzymes may also show abnormalities<sup>[1,19]</sup>. The most common laboratory findings are summarized in Table 3.

Chest CT should be preferred over plain chest X-rays because it may reveal bilateral ground glass or patchy shadowing, especially in the lower lung lobes in the great majority of patients. In patients presenting solely with GI symptoms and undergo abdominal CT scans, the radiologist should examine the lower respiratory tract to identify signs of pneumonia. However, there are patients without or minimal imaging

**Table 1** Direct comparison between severe acute respiratory syndrome coronavirus, Middle East respiratory syndrome coronavirus and severe acute respiratory syndrome coronavirus 2, based on receptor usage, primary and intermediate host, incubation period, number of cases and deaths, and basic reproduction number (R0)

Virus	Receptor	Primary host	Intermediate host	Incubation period	Number of cases (Globally)	Number of deaths (Globally)	Fatality	R0
SARS-CoV	ACE2	Bats	Raccoon dogs and civets	Approximately between 2 d and 10 d, and up to 14 d	8000	800	10%	2-5
MERS-CoV	DPP4 (CD26)	Bats	Camels	Typically, between 2 d and 14 d	2500	800	35%	2-5
SARS-CoV-2	Most likely ACE2	Bats	Pangolin ( <i>Manis pentadactyla</i> )	Current estimates between 3d to 7 d, and up to 14 d	Over 3349786 as of 03 May, 2020	Over 238628 as of 03 May, 2020	3.4% as of 3 March, 2020 <sup>[37]</sup>	2-3.5

SARS-CoV: Severe acute respiratory syndrome coronavirus; MERS-CoV: Middle East respiratory syndrome coronavirus; SARS-CoV-2: Severe acute respiratory syndrome coronavirus 2; ACE2: Angiotensin converting enzyme type 2.

**Table 2** Pulmonary findings in patients with coronavirus disease 2019

Ref.	Number of patients	Cough (n, %)	Dyspnea		Chest pain/Tightness (n, %)
			(n, %)	Sputum production (n, %)	
Wang <i>et al</i> <sup>[21]</sup>	138	82 (59.4%)	43 (31.2%)	37 (26.8)	NA
Guan <i>et al</i> <sup>[19]</sup>	1099	745 (67.8%)	205 (18.7%)	370 (33.7%)	NA
Chen <i>et al</i> <sup>[38]</sup>	99	81 (82%)	31 (31%)	NA	2 (2%)
Zhang <i>et al</i> <sup>[39]</sup>	140	90/120 (75%)	NA	NA	44/120 (36.7%)
Xu <i>et al</i> <sup>[7]</sup>	10	5 (50%)	NA	NA	NA
Jin <i>et al</i> <sup>[40]</sup>	651	53/74 (71.62%) in patients with GI symptoms 382/577 (66.2%) in patients without GI symptoms	NA	29/74 (39.19%) in patients with GI symptoms 198/577 (34.32%) in patients without GI symptoms	NA
Cheung <i>et al</i> <sup>[28]</sup>	59	22 (37.3%)	4 (6.8%)	NA	NA

GI: Gastrointestinal; NA: Not applicable.

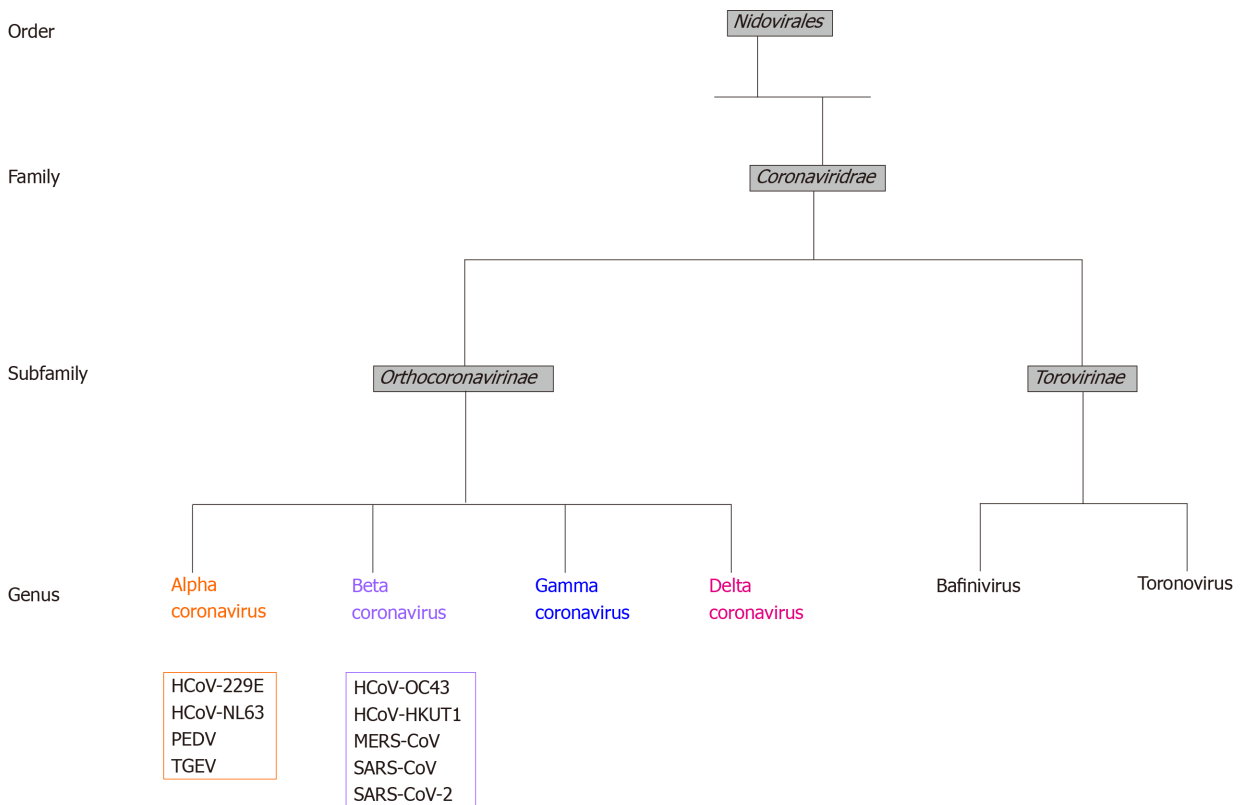
abnormalities.

COVID-19 is generally a mild disease and patients, especially children and young adults, do not develop serious respiratory symptoms. However, a proportion of patients are hospitalized with hypoxia and/or radiographic evidence of pneumonia. The course of severe disease is bi-phasic, an early phase presenting with typical respiratory viral infection symptoms followed by a sudden deterioration and complications [acute respiratory distress syndrome (61.1%), arrhythmia (44.4%) and shock (30.6%)] leading to multi-organ failure and death due to massive cytokine release syndrome<sup>[10,19,21,22]</sup>. The median hospital stay is 10 d and mortality was originally reported to be approximately 3%. However, this review has found case fatality to be approximately 1.4%<sup>[1,19,21,23]</sup>. Even though the number of deaths from SARS-CoV-2 is considered an intimidating phenomenon, according to previously published studies the Middle Eastern Respiratory Syndrome virus or SARS-CoV exhibited a higher case fatality rate<sup>[19]</sup>.

**Table 3 Presentation of laboratory findings in coronavirus disease 2019 patients**

Author	Number of patients	Most common findings	Notes/comments
Wang <i>et al</i> <sup>[21]</sup>	138	↓Lymphocytes; ↑PT; ↑LDH	Differences between ICU and non-ICU patients
Guan <i>et al</i> <sup>[19]</sup>	1099	↓Lymphocytes; ↑CRP; ↑D-dimers	Lymphopenia is common, severe in some cases
Zhang <i>et al</i> <sup>[39]</sup>	140	↓Lymphocytes; ↓Eosinophils; ↑CRP; ↑D-dimers	Correlation between blood eosinophil and lymphocyte count
Chen <i>et al</i> <sup>[38]</sup>	99	↓Hb; ↓Alb; ↑D-dimers; ↑LDH	Damage in lymphocytes, changes in immune cells
Chen <i>et al</i> <sup>[41]</sup>	113	↓Lymphocytes; ↑WBC; ↑D-dimers	Substantial differences between deceased and recovered patients

WBC: White blood cells; PT: Prothrombin time; LDH: Lactate dehydrogenase; ICU: Intensive care unit; CRP: C-reactive protein; Alb: Albumin; Hb: Hemoglobin.



**Figure 1** Phylogenetic relationship of the various types of coronaviruses within the family *Coronaviridae*, subfamily *Orthocoronavirinae* and their respective genera: Alpha, beta, gamma, and deltacoronavirus. *Coronaviridae* is the largest family within the order of *Nidovirales*. Family *Coronaviridae* includes subfamily *Torovirinae* and subfamily *Orthocoronavirinae*. Subfamily *Orthocoronavirinae* comprises four genera: Alphacoronavirus, betacoronavirus, gammacoronavirus and deltacoronavirus. Genomic characterization has shown that probably rodents and bats ate the gene sources of alphacoronavirus and betacoronavirus. The above diagram was created with Biorender.com. SARS-CoV-2: Severe acute respiratory syndrome coronavirus 2; MERS-CoV: Middle East respiratory syndrome coronavirus; SARS-CoV: Severe acute respiratory syndrome coronavirus.

## GASTROINTESTINAL MANIFESTATIONS IN ADULT AND PEDIATRIC POPULATION

Various studies from several countries have reported a variety of GI symptoms, especially nausea, abdominal pain, and diarrhea, in patients with COVID-19 (Table 4)<sup>[10,24,25,37-43]</sup>. GI symptoms are of special significance in COVID-19 patients because, in contrast to other coronaviruses, they appear early and may worsen during the course of disease, whereas in some cases may be solitary<sup>[10,26-29]</sup>. In patients, presenting solely with GI symptoms there is usually a delay in disease diagnosis and time to first respiratory symptoms, which renders these patients as a source of viral dissemination<sup>[10,23]</sup>. Thus, GI symptoms seem to be of special significance in COVID-19.

A recent review estimated a 17.6% prevalence of GI symptoms in COVID-19



**Table 4 Gastrointestinal findings in patients with coronavirus disease 2019**

Ref.	Number of patients	Anorexia / Loss of appetite (n, %)	Diarrhea (n, %)	Nausea (n, %)	Vomiting (n, %)	Abdominal pain/ discomfort (n, %)	GI bleeding (n, %)
Wang <i>et al</i> <sup>[21]</sup>	138	55 (39.9%)	14 (10.1%)	14 (10.1%)	5 (3.6%)	3 (2.2%)	NA
Guan <i>et al</i> <sup>[19]</sup>	1099	NA	42 (3.8%)	55 (5%) both for nausea and vomiting		NA	NA
Pan <i>et al</i> <sup>[22]</sup>	103	81 (78.64%)	35 (33.98%)	NA	4 (3.88%)	2 (1.94%)	NA
Zhang <i>et al</i> <sup>[39]</sup>	140	17/139 (12.2%)	18/139 (12.9%)	24/139 (17.3%)	7/139 (5%)	8/139 (5.8%)	NA
Fang <i>et al</i> <sup>[30]</sup>	305	101/201 (50.2%)	146/295 (49.5%)	59/201 (29.4%)	32/201 (15.9%)	12/201 (6%)	NA
Lin <i>et al</i> <sup>[42]</sup>	95 (58 with GI manifestations)	17 (17.9%)	23 (24.2%)	17 (17.9%)	4 (4.2%)	2 (2.1%)	2 (2.1%)
Cheung <i>et al</i> <sup>[28]</sup>	59 (15 with GI manifestations)	NA	13 (22%)	NA	1 (1.7%)	7 (11.9%)	NA
Xia <i>et al</i> <sup>[43]</sup>	20	NA	3 (15%)	NA	2 (10%)	NA	NA
Xiao <i>et al</i> <sup>[6]</sup>	73	NA	26 (35.6%)	NA	NA	NA	10 (13.7%)

GI: Gastrointestinal.

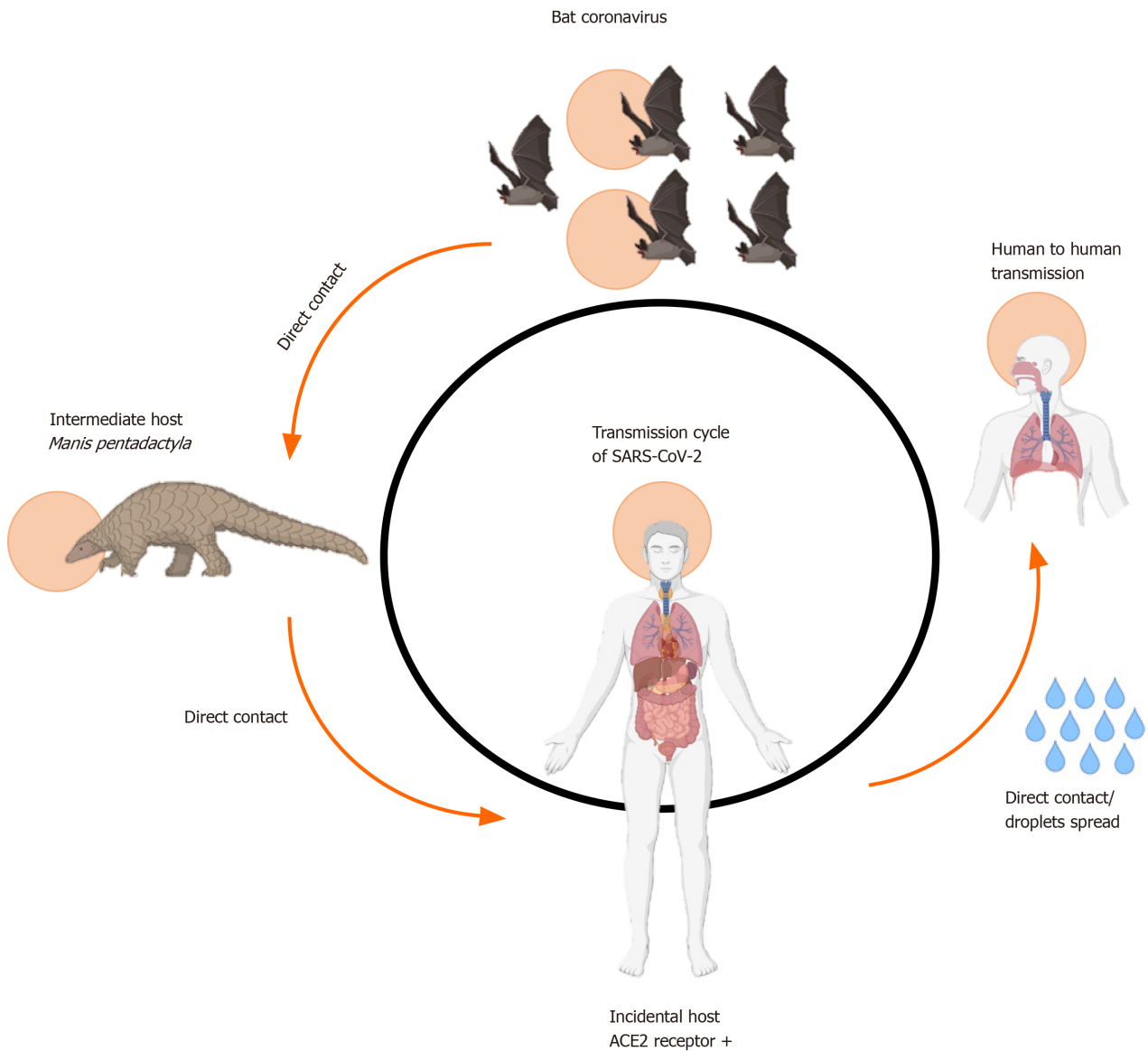
patients<sup>[28]</sup>. The exact incidence of digestive symptoms is a matter of debate, with anorexia being reported as the most common symptom in one study (39.9%-50.2%), whereas diarrhea posing as most common in both adult and pediatric populations in other studies (2%-49.5%)<sup>[24,25]</sup>. Notably, Fang *et al*<sup>[30]</sup> corroborated the incidence of diarrhea and found that more than 50% of reported diarrhea occurred following admission and initiation of antiviral therapy, with approximately 22.2% complaining about loose stool before COVID-19 diagnosis. Excluding anorexia as non-specific, approximately 20% of patients develop GI symptoms. Gastrointestinal symptoms usually worsen with disease progression and signifies a more insidious onset of disease<sup>[22]</sup>. There are also reports in the literature of acute hemorrhagic colitis as well as GI bleeding<sup>[22,25,31]</sup>.

Interestingly, as aforementioned, a small number of patients seem to exhibit solely GI symptoms like vomiting and diarrhea without concomitant respiratory manifestations. Worthy of note is the first confirmed case of SARS-CoV-2 infection in the United States, where the patient had been reportedly suffering from a 2 d history of vomiting and diarrhea before admission<sup>[32]</sup>. A portion of those patients only manifests fever a few days following admission<sup>[7,25]</sup>. The latter demands a high level of awareness among clinicians, because patients are still admitted in non-COVID-19 wards for GI symptoms and this could represent a potential infection hazard, as was described by Zhang *et al*<sup>[23]</sup> in the Lancet.

What is also worthy of mention here is that the presence of digestive symptoms and specifically diarrhea is associated with a higher incidence of stool positivity for viral RNA as well as a higher viral load for SARS-CoV-2 RNA. The presence of viral RNA in stool was detected in almost half (48.1%) of the patients<sup>[28]</sup>, with a reported duration of 33-47 d after the first onset of disease and even after clearance of nasal-throat RT-PCR samples compared to approximately 9% of patients without GI symptoms<sup>[28,33]</sup>.

SARS-CoV-2 may cause liver injury which is similar to respiratory coronaviruses, with which it shares genome<sup>[23]</sup>, but its incidence is less common than that of SARS-CoV infection (5%-37% *vs* up to 60%)<sup>[10,19]</sup>. Mild to moderate elevation of aminotransferases is often reported, but signs of significant liver injury are rather rare. On the contrary, higher rates of GI symptoms and liver injury with greater elevations of aminotransferases, are associated with severe disease and are often seen in Intensive Care Unit patients<sup>[21-23]</sup>. To date, there has been one case report of SARS-CoV-2 infection manifesting as acute hepatitis, without the presence of any respiratory symptoms, in a patient under therapy for HIV infection<sup>[27]</sup>.

Lastly, data regarding children with COVID-19 is scarce. Although clinical presentation is similar to that in adults, i.e. upper respiratory symptoms (dry cough, nasal congestion, pharyngalgia) and diarrhea, pediatric patients develop milder clinical manifestations and biochemical and radiological abnormalities are less



**Figure 2 Transmission cycle of severe acute respiratory syndrome coronavirus 2.** The above diagram was created with <http://www.Biorender.com>. SARS-CoV-2: Severe acute respiratory syndrome coronavirus 2; ACE2: Angiotensin converting enzyme type 2.

pronounced than in adults<sup>[7]</sup>. Specifically, high fever, lymphopenia, leukopenia or leukocytosis, and elevated transaminases are seldom seen in children<sup>[7]</sup>. Nevertheless, there are recent reports from United Kingdom and other Western countries of cases of critically ill children presenting with features of multisystem inflammatory state, similar to toxic shock syndrome and Kawasaki disease linked to COVID-19, but further research on this topic is expected<sup>[34,35]</sup>.

Finally, and in addition of the above, as these GI symptoms are not specific and may develop in patients without COVID-19, such as patients with peptic ulcer disease, inflammatory bowel disease, other gastrointestinal infections, intake of NSAIDs, antibiotics, PPIs, or traditional remedies etc., it is of utmost importance that physicians and radiologists are fully aware to suspect underlying COVID-19 even in patients with pre-existing GI conditions<sup>[36]</sup>.

## PATHOPHYSIOLOGY OF GASTROINTESTINAL AND LIVER MANIFESTATIONS

As discussed previously, SARS-CoV-2 enters and replicates into cells by binding to its ACE2 receptor<sup>[8]</sup>. ACE2 receptor is expressed in type 2 alveolar cells, but abundant expression of ACE2 has been found in epithelial cells throughout the GI tract and

cholangiocytes<sup>[8]</sup>. Distribution of ACE2 staining positivity is mainly in the cytoplasm of the epithelial cells of the stomach and intestine and the cilia of glandular epithelial cells. In COVID-19 patients, the presence of viral nucleocapsid protein has been verified in almost the entirety of the GI lumen, such as gastric, duodenal and rectal glandular epithelial cells, apart from the esophagus. From a histological point of view, the epithelium of the digestive tract shows plasmacytic and lymphocytic infiltration with interstitial edema, mainly in the stomach, duodenum and rectum and more patchy lymphocytic infiltration in the esophagus. Thus, SARS-CoV-2 may cause digestive symptoms either by direct viral invasion in target cells and/or immune-mediated tissue and end-organ injury<sup>[8,25]</sup>. However, symptoms of COVID-19 might be indirectly caused by infection-induced respiratory complications, which lead to tissue hypoxia, loss of cell integrity, cell injury and finally cell death. In favor of this hypothesis is the common use of antibiotics, NSAIDs and corticosteroids for the treatment of tissue hypoxia in critically ill patients<sup>[25]</sup>. However, as many patients developed diarrhea after hospitalization or after administration of medication, drug-induced GI manifestations, such as nausea, abdominal pain, and diarrhea, cannot be excluded<sup>[25]</sup>.

Liver exposure to SARS-CoV-2 is unavoidable. The presence of ACE2 receptors in cholangiocytes supports a retrograde mode of liver damage following the entrance of the virus in bile tree cells<sup>[7,23]</sup>. Liver biopsies confirm the presence of viral RNA in liver tissues. Furthermore, atypical signs of hepatocyte injury have been presented, such as cell apoptosis along with ballooning, acidophilic bodies and lobular inflammation, corroborating the mechanism of direct viral injury<sup>[10]</sup>. Liver injury may also be induced by treatment, as drugs particularly associated with liver injury, such as antibiotics, antiretrovirals and NSAIDs, are regularly administered to COVID-19 patients. Last but not least, SARS-CoV-2 may trigger the massive release of pro-inflammatory cytokines leading to cardio-pulmonary manifestations, tissue hypoxia and thrombosis, which may cause or exacerbate underlying liver injury<sup>[23]</sup>.

---

## COVID-19 AND ITS IMPACT ON CHRONIC LIVER DISEASES

---

The impact of SARS-CoV-2 on chronic liver diseases remains largely unknown and under investigation. Guan *et al*<sup>[19]</sup> found that patients with pre-existing hepatitis B infection had a more severe course of COVID-19 indicating that SARS-CoV-2 replication and persistent liver injury need further investigation in patients with chronic HBV hepatitis/infection on long-term treatment. Furthermore, screening of liver donors for SARS-CoV-2 and/or active COVID-19 is essential before liver transplantation to avoid transmission of the virus to the graft recipient. Preliminary studies suggest that patients with cancer or liver cirrhosis are more susceptible to SARS-CoV-2 infection, probably because of their immunocompromised status<sup>[23,36]</sup>. Data on other chronic liver conditions, such as non-alcoholic fatty liver disease, alcohol-related liver disease and autoimmune hepatitis are very limited and the impact of SARS-COV-2 liver injury should be further investigated. The severity and incidence of complications in these patients, including secondary infection, hepatic encephalopathy and liver failure should also be examined.

---

## CONCLUSION

---

The respiratory system is the primary route for transmission of COVID-19. Several studies have proposed that the GI tract is affected by SARS-CoV-2, but an oral-fecal route of transmission has not yet been documented. Patients with COVID-19 may develop a variety of GI manifestations, which may pre-exist or not be accompanied by respiratory symptoms. Clinicians should be alerted and not underestimate or disregard these early or mild GI symptoms because patients may be infected and transmit the virus. Liver injury may also occur during COVID-19 but seems to be multifactorial. The time window between fecal and respiratory PCR tests show that viral RNA shedding persists for longer periods. Further research is needed to confirm whether RT-PCR testing in feces in combination with respiratory tract tests are helpful to assess the presence of infectious virus and the termination of quarantine.



## REFERENCES

- 1 **Cascella M**, Rajnik M, Cuomo A, Dulebohn SC, Di Napoli R. Features, Evaluation and Treatment Coronavirus (COVID-19) 2020; [PMID: [32150360](#)]
- 2 **Wang C**, Horby PW, Hayden FG, Gao GF. A novel coronavirus outbreak of global health concern. *Lancet* 2020; **395**: 470-473 [PMID: [31986257](#) DOI: [10.1016/S0140-6736\(20\)30185-9](#)]
- 3 **Zhu N**, Zhang D, Wang W, Li X, Yang B, Song J, Zhao X, Huang B, Shi W, Lu R, Niu P, Zhan F, Ma X, Wang D, Xu W, Wu G, Gao GF, Tan W; China Novel Coronavirus Investigating and Research Team. A Novel Coronavirus from Patients with Pneumonia in China, 2019. *N Engl J Med* 2020; **382**: 727-733 [PMID: [31978945](#) DOI: [10.1056/NEJMoa2001017](#)]
- 4 **Jiang F**, Deng L, Zhang L, Cai Y, Cheung CW, Xia Z. Review of the Clinical Characteristics of Coronavirus Disease 2019 (COVID-19). *J Gen Intern Med* 2020; **35**: 1545-1549 [PMID: [32133578](#) DOI: [10.1007/s11606-020-05762-w](#)]
- 5 **Chang L**, Yan Y, Wang L. Coronavirus Disease 2019: Coronaviruses and Blood Safety. *Transfus Med Rev* 2020; **34**: 75-80 [PMID: [32107119](#) DOI: [10.1016/j.tmr.2020.02.003](#)]
- 6 **WHO**. Coronavirus disease 2019. Situation Report- 104. 2020; Available from: <https://www.who.int/emergencies/diseases/novel-coronavirus-2019>
- 7 **Xu Y**, Li X, Zhu B, Liang H, Fang C, Gong Y, Guo Q, Sun X, Zhao D, Shen J, Zhang H, Liu H, Xia H, Tang J, Zhang K, Gong S. Characteristics of pediatric SARS-CoV-2 infection and potential evidence for persistent fecal viral shedding. *Nat Med* 2020; **26**: 502-505 [PMID: [32284613](#) DOI: [10.1038/s41591-020-0817-4](#)]
- 8 **Xiao F**, Tang M, Zheng X, Liu Y, Li X, Shan H. Evidence for Gastrointestinal Infection of SARS-CoV-2. *Gastroenterology* 2020; **158**: 1831-1833.e3 [PMID: [32142773](#) DOI: [10.1053/j.gastro.2020.02.055](#)]
- 9 **Wang W**, Xu Y, Gao R, Lu R, Han K, Wu G, Tan W. Detection of SARS-CoV-2 in Different Types of Clinical Specimens. *JAMA* 2020 [PMID: [32159775](#) DOI: [10.1001/jama.2020.3786](#)]
- 10 **Gu J**, Han B, Wang J. COVID-19: Gastrointestinal Manifestations and Potential Fecal-Oral Transmission. *Gastroenterology* 2020; **158**: 1518-1519 [PMID: [32142785](#) DOI: [10.1053/j.gastro.2020.02.054](#)]
- 11 **Ng SC**, Tilg H. COVID-19 and the gastrointestinal tract: more than meets the eye. *Gut* 2020; **69**: 973-974 [PMID: [32273292](#) DOI: [10.1136/gutjnl-2020-321195](#)]
- 12 **Ashour HM**, Elkhatib WF, Rahman MM, Elshabrawy HA. Insights into the Recent 2019 Novel Coronavirus (SARS-CoV-2) in Light of Past Human Coronavirus Outbreaks. *Pathogens* 2020; **9** [PMID: [32143502](#) DOI: [10.3390/pathogens9030186](#)]
- 13 **Guo YR**, Cao QD, Hong ZS, Tan YY, Chen SD, Jin HJ, Tan KS, Wang DY, Yan Y. The origin, transmission and clinical therapies on coronavirus disease 2019 (COVID-19) outbreak - an update on the status. *Mil Med Res* 2020; **7**: 11 [PMID: [32169119](#) DOI: [10.1186/s40779-020-00240-0](#)]
- 14 **Ding Y**, Wang H, Shen H, Li Z, Geng J, Han H, Cai J, Li X, Kang W, Weng D, Lu Y, Wu D, He L, Yao K. The clinical pathology of severe acute respiratory syndrome (SARS): a report from China. *J Pathol* 2003; **200**: 282-289 [PMID: [12845623](#) DOI: [10.1002/path.1440](#)]
- 15 **de Wit E**, van Doremalen N, Falzarano D, Munster VJ. SARS and MERS: recent insights into emerging coronaviruses. *Nat Rev Microbiol* 2016; **14**: 523-534 [PMID: [27344959](#) DOI: [10.1038/nrmicro.2016.81](#)]
- 16 **Chen Y**, Liu Q, Guo D. Emerging coronaviruses: Genome structure, replication, and pathogenesis. *J Med Virol* 2020; **92**: 418-423 [PMID: [31967327](#) DOI: [10.1002/jmv.25681](#)]
- 17 **Zhou P**, Yang XL, Wang XG, Hu B, Zhang L, Zhang W, Si HR, Zhu Y, Li B, Huang CL, Chen HD, Chen J, Luo Y, Guo H, Jiang RD, Liu MQ, Chen Y, Shen XR, Wang X, Zheng XS, Zhao K, Chen QJ, Deng F, Liu LL, Yan B, Zhan FX, Wang YY, Xiao GF, Shi ZL. A pneumonia outbreak associated with a new coronavirus of probable bat origin. *Nature* 2020; **579**: 270-273 [PMID: [32015507](#) DOI: [10.1038/s41586-020-2012-7](#)]
- 18 **Li Q**, Guan X, Wu P, Wang X, Zhou L, Tong Y, Ren R, Leung KSM, Lau EHY, Wong JY, Xing X, Xiang N, Wu Y, Li C, Chen Q, Li D, Liu T, Zhao J, Liu M, Tu W, Chen C, Jin L, Yang R, Wang Q, Zhou S, Wang R, Liu H, Luo Y, Liu Y, Shao G, Li H, Tao Z, Yang Y, Deng Z, Liu B, Ma Z, Zhang Y, Shi G, Lam TTY, Wu JT, Gao GF, Cowling BJ, Yang B, Leung GM, Feng Z. Early Transmission Dynamics in Wuhan, China, of Novel Coronavirus-Infected Pneumonia. *N Engl J Med* 2020; **382**: 1199-1207 [PMID: [31995857](#) DOI: [10.1056/NEJMoa2001316](#)]
- 19 **Guan WJ**, Ni ZY, Hu Y, Liang WH, Ou CQ, He JX, Liu L, Shan H, Lei CL, Hui DSC, Du B, Li LJ, Zeng G, Yuen KY, Chen RC, Tang CL, Wang T, Chen PY, Xiang J, Li SY, Wang JL, Liang ZJ, Peng YX, Wei L, Liu Y, Hu YH, Peng P, Wang JM, Liu JY, Chen Z, Li G, Zheng ZJ, Qiu SQ, Luo J, Ye CJ, Zhu SY, Zhong NS; China Medical Treatment Expert Group for Covid-19. Clinical Characteristics of Coronavirus Disease 2019 in China. *N Engl J Med* 2020; **382**: 1708-1720 [PMID: [32109013](#) DOI: [10.1056/NEJMoa2002032](#)]
- 20 **D'Amico F**, Baumgart DC, Danese S, Peyrin-Biroulet L. Diarrhea During COVID-19 Infection: Pathogenesis, Epidemiology, Prevention, and Management. *Clin Gastroenterol Hepatol* 2020; **18**: 1663-1672 [PMID: [32278065](#) DOI: [10.1016/j.cgh.2020.04.001](#)]
- 21 **Wang D**, Hu B, Hu C, Zhu F, Liu X, Zhang J, Wang B, Xiang H, Cheng Z, Xiong Y, Zhao Y, Li Y, Wang X, Peng Z. Clinical Characteristics of 138 Hospitalized Patients With 2019 Novel Coronavirus-Infected Pneumonia in Wuhan, China. *JAMA* 2020 [PMID: [32031570](#) DOI: [10.1001/jama.2020.1585](#)]
- 22 **Pan L**, Mu M, Yang P, Sun Y, Wang R, Yan J, Li P, Hu B, Wang J, Hu C, Jin Y, Niu X, Ping R, Du Y, Li T, Xu G, Hu Q, Tu L. Clinical Characteristics of COVID-19 Patients With Digestive Symptoms in Hubei, China: A Descriptive, Cross-Sectional, Multicenter Study. *Am J Gastroenterol* 2020; **115**: 766-773 [PMID: [32287140](#) DOI: [10.14309/ajg.0000000000000620](#)]
- 23 **Zhang C**, Shi L, Wang FS. Liver injury in COVID-19: management and challenges. *Lancet Gastroenterol Hepatol* 2020; **5**: 428-430 [PMID: [32145190](#) DOI: [10.1016/S2468-1253\(20\)30057-1](#)]
- 24 **Ungaro RC**, Sullivan T, Colombel JF, Patel G. What Should Gastroenterologists and Patients Know About COVID-19? *Clin Gastroenterol Hepatol* 2020; **18**: 1409-1411 [PMID: [32197957](#) DOI: [10.1016/j.cgh.2020.03.020](#)]
- 25 **Tian Y**, Rong L, Nian W, He Y. Review article: gastrointestinal features in COVID-19 and the possibility of faecal transmission. *Aliment Pharmacol Ther* 2020; **51**: 843-851 [PMID: [32222988](#) DOI: [10.1111/apt.15731](#)]
- 26 **Liang W**, Feng Z, Rao S, Xiao C, Xue X, Lin Z, Zhang Q, Qi W. Diarrhoea may be underestimated: a

- missing link in 2019 novel coronavirus. *Gut* 2020; **69**: 1141-1143 [PMID: 32102928 DOI: 10.1136/gutjnl-2020-320832]
- 27 **Wander P**, Epstein M, Bernstein D. COVID-19 Presenting as Acute Hepatitis. *Am J Gastroenterol* 2020; **115**: 941-942 [PMID: 32301760 DOI: 10.14309/ajg.0000000000000660]
  - 28 **Cheung KS**, Hung IFN, Chan PPY, Lung KC, Tso E, Liu R, Ng YY, Chu MY, Chung TWH, Tam AR, Yip CCY, Leung KH, Fung AY, Zhang RR, Lin Y, Cheng HM, Zhang AJX, To KKW, Chan KH, Yuen KY, Leung WK. Gastrointestinal Manifestations of SARS-CoV-2 Infection and Virus Load in Fecal Samples From a Hong Kong Cohort: Systematic Review and Meta-analysis. *Gastroenterology* 2020; **159**: 81-95 [PMID: 32251668 DOI: 10.1053/j.gastro.2020.03.065]
  - 29 **An P**, Chen H, Jiang X, Su J, Xiao Y, Ding Y, Ren H, Ji M, Chen Y, Chen W, Lv X, Shen L, Chen M, Li J, Yin A, Kang J, Liu S, Tan W, Wu L, Dong W, Cao J, Zhou Z, Tan S, Chen G, Zhou J, Yang Y, Yu H. Clinical Features of 2019 Novel Coronavirus Pneumonia Presented Gastrointestinal Symptoms But Without Fever Onset. *SSRN Electron J* 2020 [DOI: 10.2139/ssrn.3532530]
  - 30 **Fang D**, Ma JD, Guan JL. Manifestations of Digestive system in hospitalized patients with novel coronavirus pneumonia in Wuhan, China: a single-center, descriptive study. *Zhonghua Xiaohua Zazhi* 2020; **40**: E005–E005 [DOI: 10.3760/CMA.J.ISSN.0254-1432.2020.0005]
  - 31 **Carvalho A**, Alqusairi R, Adams A, Paul M, Kothari N, Peters S, DeBenedet AT. SARS-CoV-2 Gastrointestinal Infection Causing Hemorrhagic Colitis: Implications for Detection and Transmission of COVID-19 Disease. *Am J Gastroenterol* 2020; **115**: 942-946 [PMID: 32496741 DOI: 10.14309/ajg.0000000000000667]
  - 32 **Holshue ML**, DeBolt C, Lindquist S, Lofy KH, Wiesman J, Bruce H, Spitters C, Ericson K, Wilkerson S, Tural A, Diaz G, Cohn A, Fox L, Patel A, Gerber SI, Kim L, Tong S, Lu X, Lindstrom S, Pallansch MA, Weldon WC, Biggs HM, Uyeki TM, Pillai SK; Washington State 2019-nCoV Case Investigation Team. First Case of 2019 Novel Coronavirus in the United States. *N Engl J Med* 2020; **382**: 929-936 [PMID: 32004427 DOI: 10.1056/NEJMoa2001191]
  - 33 **Wu Y**, Guo C, Tang L, Hong Z, Zhou J, Dong X, Yin H, Xiao Q, Tang Y, Qu X, Kuang L, Fang X, Mishra N, Lu J, Shan H, Jiang G, Huang X. Prolonged presence of SARS-CoV-2 viral RNA in faecal samples. *Lancet Gastroenterol Hepatol* 2020; **5**: 434-435 [PMID: 32199469 DOI: 10.1016/S2468-1253(20)30083-2]
  - 34 **Mahase E**. Covid-19: concerns grow over inflammatory syndrome emerging in children. *BMJ* 2020; **369**: m1710 [PMID: 32345602 DOI: 10.1136/bmj.m1710]
  - 35 **Jones VG**, Mills M, Suarez D, Hogan CA, Yeh D, Segal JB, Nguyen EL, Barsh GR, Maskatia S, Mathew R. COVID-19 and Kawasaki Disease: Novel Virus and Novel Case. *Hosp Pediatr* 2020; **10**: 537-540 [PMID: 32265235 DOI: 10.1542/hpeds.2020-0123]
  - 36 **Mao R**, Liang J, Shen J, Ghosh S, Zhu LR, Yang H, Wu KC, Chen MH; Chinese Society of IBD, Chinese Elite IBD Union; Chinese IBD Quality Care Evaluation Center Committee. Implications of COVID-19 for patients with pre-existing digestive diseases. *Lancet Gastroenterol Hepatol* 2020; **5**: 425-427 [PMID: 32171057 DOI: 10.1016/S2468-1253(20)30076-5]
  - 37 **WHO**. WHO Director-General's opening remarks at the media briefing on COVID-19-3 March, 2020. 2020; Available from: <https://www.who.int/dg/speeches/detail/who-director-general-s-opening-remarks-at-the-media-briefing-on-covid-19---3-march-2020>
  - 38 **Chen N**, Zhou M, Dong X, Qu J, Gong F, Han Y, Qiu Y, Wang J, Liu Y, Wei Y, Xia J, Yu T, Zhang X, Zhang L. Epidemiological and clinical characteristics of 99 cases of 2019 novel coronavirus pneumonia in Wuhan, China: a descriptive study. *Lancet* 2020; **395**: 507-513 [PMID: 32007143 DOI: 10.1016/S0140-6736(20)30211-7]
  - 39 **Zhang JJ**, Dong X, Cao YY, Yuan YD, Yang YB, Yan YQ, Akdis CA, Gao YD. Clinical characteristics of 140 patients infected with SARS-CoV-2 in Wuhan, China. *Allergy* 2020; **75**: 1730-1741 [PMID: 32077115 DOI: 10.1111/all.14238]
  - 40 **Jin X**, Lian JS, Hu JH, Gao J, Zheng L, Zhang YM, Hao SR, Jia HY, Cai H, Zhang XL, Yu GD, Xu KJ, Wang XY, Gu JQ, Zhang SY, Ye CY, Jin CL, Lu YF, Yu X, Yu XP, Huang JR, Xu KL, Ni Q, Yu CB, Zhu B, Li YT, Liu J, Zhao H, Zhang X, Yu L, Guo YZ, Su JW, Tao JJ, Lang GJ, Wu XX, Wu WR, Qv TT, Xiang DR, Yi P, Shi D, Chen Y, Ren Y, Qiu YQ, Li LJ, Sheng J, Yang Y. Epidemiological, clinical and virological characteristics of 74 cases of coronavirus-infected disease 2019 (COVID-19) with gastrointestinal symptoms. *Gut* 2020; **69**: 1002-1009 [PMID: 32213556 DOI: 10.1136/gutjnl-2020-320926]
  - 41 **Chen T**, Wu D, Chen H, Yan W, Yang D, Chen G, Ma K, Xu D, Yu H, Wang H, Wang T, Guo W, Chen J, Ding C, Zhang X, Huang J, Han M, Li S, Luo X, Zhao J, Ning Q. Clinical characteristics of 113 deceased patients with coronavirus disease 2019: retrospective study. *BMJ* 2020; **368**: m1091 [PMID: 32217556 DOI: 10.1136/bmj.m1091]
  - 42 **Lin L**, Jiang X, Zhang Z, Huang S, Zhang Z, Fang Z, Gu Z, Gao L, Shi H, Mai L, Liu Y, Lin X, Lai R, Yan Z, Li X, Shan H. Gastrointestinal symptoms of 95 cases with SARS-CoV-2 infection. *Gut* 2020; **69**: 997-1001 [PMID: 32241899 DOI: 10.1136/gutjnl-2020-321013]
  - 43 **Xia W**, Shao J, Guo Y, Peng X, Li Z, Hu D. Clinical and CT features in pediatric patients with COVID-19 infection: Different points from adults. *Pediatr Pulmonol* 2020; **55**: 1169-1174 [PMID: 32134205 DOI: 10.1002/ppul.24718]



Published by **Baishideng Publishing Group Inc**  
7041 Koll Center Parkway, Suite 160, Pleasanton, CA 94566, USA

**Telephone:** +1-925-3991568

**E-mail:** [bpgoffice@wjgnet.com](mailto:bpgoffice@wjgnet.com)

**Help Desk:** <https://www.f6publishing.com/helpdesk>

<https://www.wjgnet.com>

